

Neovascular Glaucoma: Etiology, Diagnosis and Prognosis

Tarek A. Shazly

Department of Ophthalmology,
Massachusetts Eye and Ear
Infirmary, Boston, MA, USA, and
Department of Ophthalmology,
Assiut University Hospital, Assiut,
Egypt

Mark A. Latina

Department of Ophthalmology,
Massachusetts Eye and Ear
Infirmary, Boston, MA, USA and
Department of Ophthalmology, Tufts
University School of Medicine,
Boston, MA, USA

ABSTRACT

Neovascular glaucoma (NVG) is a severe form of glaucoma with devastating visual outcome attributed to new blood vessels obstructing aqueous humor outflow, usually secondary to widespread posterior segment ischemia. Invasion of the anterior chamber by a fibrovascular membrane initially obstructs aqueous outflow in an open-angle fashion and later contracts to produce secondary synechial angle-closure glaucoma. The full blown picture of NVG is characterized by iris neovascularization, a closed anterior chamber angle, and extremely high intraocular pressure (IOP) with severe ocular pain and usually poor vision.

Keywords: neovascular glaucoma; rubeotic glaucoma; neovascularization; retinal ischemia; vascular endothelial growth factor (VEGF); proliferative diabetic retinopathy; central retinal vein occlusion

INTRODUCTION

The written history of NVG began in 1906, when neovascularization was first reported by Coats in the histopathologic specimens of the iris of patients with central retinal vein occlusion (CRVO), and later on in patients with diabetes by Salus.^{1,2} Since then, cumulative data provided better understanding of the relation between neovascularization and chronic synechial angle closure.³ It was not until 1963 when Weiss et al. suggested the term *neovascular glaucoma* to replace the older terms, such as Hemorrhagic glaucoma, thrombotic glaucoma, congestive glaucoma, rubeotic glaucoma, diabetic hemorrhagic glaucoma, and 100 day glaucoma.⁴ NVG is a serious, yet preventable, complication with significant potential for visual loss. Once NVG is well established, the likelihood for successful outcome is markedly reduced. So far, we still do not have a defini-

tive means of reversing well established NVG and preventing visual loss in the majority of cases; instead better understanding of underlying etiology, pathogenesis, and clinical course can improve the care provider's ability to promptly recognize this complication at an early stage and properly treat the underlying cause, hence improving the visual outcomes of this relatively common blinding condition.⁵

AETIOLOGY

NVG is usually secondary to posterior segment disease involving hypoxic retina, which in turn produces angiogenic factors that stimulate new vessel proliferation in the anterior segment.

A long list of ocular and systemic disorders may lead to NVG,⁶ but diabetes mellitus, CRVO, and ocular ischemic syndrome (OIS) are the primary underlying diseases to consider, as noted in Table 1. The pathogenesis of NVG is beyond the scope of this review.

Address correspondence to Tarek A. Shazly, MD, 20 Pondmeadow Drive, Suite # 203, Reading, MA 01867, USA. E-mail: Ophth_inventor@yahoo.com

Table 1. Factors predisposing to iris neovascularization and neovascular glaucoma

Retinal Ischemic Disease	Tumors
Diabetic retinopathy	Choroidal melanoma
Central retinal vein occlusion	Ring melanoma of the ciliary body
Central retinal artery occlusion	Iris melanoma
Branch retinal vein occlusion	Retinoblastoma
Branch retinal artery occlusion	Large cell lymphoma
Combined retinal artery/vein obstruction	Metastatic carcinoma
Retinal detachment	Reticulum cell sarcoma
Hemorrhagic retinal disorders	Inflammatory Diseases
Coat's exudative retinopathy	Uveitis: chronic iridocyclitis, Behçet disease
Eale disease	Vogt-Koyanagi-Harada syndrome
Leber's congenital amaurosis	Sympathetic ophthalmia
Retinopathy of prematurity	Endophthalmitis
Persistent hyperplastic primary vitreous	Crohn disease with retinal vasculitis
Sickle cell retinopathy	
Syphilitic retinal vasculitis	
Retinoschisis	
Stickler syndrome (inherited vitreoretinal degeneration)	Surgical Causes
Optic nerve glioma with subsequent venous stasis retinopathy	Carotid endarterectomy
Angiomatosis retinae (Von Hippel's disease)	Cataract extraction
Sturge-Weber, choroidal hemangioma	Pars plana vitrectomy or lensectomy
Familial exudative vitreoretinopathy of Criswick and Schepens	Nd:YAG capsulotomy
	Laser coreoplasty
Irradiation	Extraocular Vascular Disorders
Photoradiation	Carotid artery obstructive disease
External beam	Carotid-cavernous fistula
Charged particle: proton, helium ion radiation	Internal carotid artery occlusion
Plaques	Giant cell arteritis
	Takayasu's disease (pulseless disease)

Adapted and modified from Sivak-Callcott JA, O'Day DM, Gass DM, et al. Evidence-based recommendations for the diagnosis and treatment of neovascular glaucoma. *Ophthalmology* 2001;108:1767-1778.

Retinal Vascular Disorders

Central Retinal Vein Occlusion (CRVO)

Central retinal vein occlusion was reported to be responsible for 28% of cases of rubeosis iridis.⁷ According to the Central Vein Occlusion Study (CVOS) incidence of neovascular glaucoma, following CRVO was 16%.⁷

The incidence of rubeosis iridis and neovascular glaucoma in CRVO patients is significantly correlated with the extent of retinal capillary nonperfusion.⁸⁻¹⁰ The association of NVG with retinal ischemia, as documented by fluorescein angiography, can be as high as 60%.¹¹ Identifying retinal ischemia with fluorescein angiography is sometimes challenging, due to the presence of hemorrhages and media opacities.

One third of the initially non-ischemic CRVO eyes can convert to ischemic CRVO, defined as greater than 10 disc diameters within 3 years.⁷

The most reliable predictor of NVG following CRVO is visual acuity. As reported by CVOS, over 30% of eyes with acuity less than 20/200 within 1 month of the occlusion developed anterior segment neovascularization, while the incidence is as low as 5% for those who present with visual acuity of 20/40 or better.⁷ Classically NVG occurs within 3 months of the CRVO, hence the name 100 day glaucoma. Over 80% appear within the first 6 months.¹⁰

Approximately 25% of all patients with CRVO have concomitant open-angle glaucoma, with an even higher incidence in elderly patients.^{10,12}

Branch Retinal Vein Occlusion (BRVO)

Branch retinal vein occlusion may rarely cause rubeosis iridis¹³ and neovascular glaucoma,¹⁴ yet the incidence is very low as the risk of NVG is proportionate to the extent of retinal ischemia.

Diabetic Retinopathy

Iris neovascularization classically develops in patients with longstanding diabetes, usually in relation to proliferative diabetic retinopathy (PDR), especially with optic disc neovascularization.¹⁵ In patients with PDR, incidence of rubeosis iridis is reported to be 50%.^{16,17} Development of rubeosis iridis in an eye with non-proliferative retinopathy without significant retinal ischemia should attract the attention to other coexisting conditions such as carotid artery disease and ocular ischemic syndrome.

The risk of NVG is significantly increased following vitrectomy and lensectomy for diabetic retinopathy, as a result of better access of the vasoproliferative mediators to the anterior segment.^{18–20}

Central Retinal Artery Occlusion

Central retinal artery occlusion (CRAO) is an uncommon cause of NVG, probably because the complete ischemia that occurs in CRAO completely destroys the inner retina and diminishes production of angiogenic factors. Iris neovascularization tends to develop early, hence the name 30 day glaucoma. The estimated incidence of NVG following CRAO is between 5 and 10%.²¹ This incidence tends to be higher if CRAO was secondary to carotid artery occlusion or was combined with CRVO.

Branch Retinal Artery Occlusion (BRAO)

Branch retinal artery occlusion was also reported as a rare cause of rubeosis iridis.^{22,23}

Extraocular Vascular Disease

Extraocular. Vascular diseases can also produce retinal hypoxia and NVG. Carotid artery obstructive disease is the third most common cause of neovascular glaucoma, being responsible for 13% of all cases.²⁴ In addition to causing NVG by itself, it can contribute to CRVO and proliferative diabetic retinopathy.^{25,26}

A unique feature of NVG secondary to carotid artery obstructive disease is that those eyes may initially present with normal or even low IOP due to ischemia of the ciliary body with reduced aqueous production.²⁷ This paradoxically low IOP in eyes with well established NVG should suggest carotid artery obstructive disease.²⁸ The fundus will show peripherally located, scattered hemorrhages that can be easily missed. NVG may develop secondary to carotid-cavernous sinus fistula,²⁹ before or after embolic therapy, due to the reduction in the ocular perfusion pressure.^{30,31} Temporal arteritis is another example of an extraocular vascular disease causing NVG.³²

Other Posterior Segment Disorders

Retinal detachment. Iris neovascularization and NVG were reported to develop secondarily to rhegmatogenous retinal detachment, mediated by the release of angiogenic factors from the detached retina or retinal pigment epithelium, especially when detachment is complicated by proliferative vitreoretinopathy.^{33,34} On the other hand successful retinal detachment surgery may cause neovascularization due to anterior segment ischemia from trauma to the anterior ciliary arteries.³⁴

Posterior uveitis. Posterior uveitis and scleritis are more likely to produce NVG than iridocyclitis, via the release of angiogenic factors secondary to inflammatory effect on retinal vascular perfusion.³⁵

Tumors. NVG can develop in patients with intraocular tumours, malignant melanoma, and retinoblastoma being the most common.^{36,37} Large retinoblastomas, with secondary retinal detachment and necrosis are more likely to develop iris neovascularization.³⁸

DIAGNOSIS

The signs and symptoms of neovascularization vary with the stage of the disease. Gonioscopy and careful slit lamp examination under high magnification are mandatory to diagnose the early stages of NVG in at risk patients. The clinical course of NVG typically comprises four stages.³⁹

In the *prerubeosis stage*, the anterior segment examination is unremarkable, with normal IOP. The clinical findings would be related to the initial retinal ischemic disorder, such as PDR or CRVO. Identifying patients to be at risk of neovascular glaucoma at this stage is of utmost importance, as that is the best time to intervene to prevent NVG.

In the *preglaucoma stage*, in addition to the retinal ischemic condition, iris neovascularization starts to develop, without a change in the IOP. Iris neovascularization appears first as fine peri-pupillary tuft of vessels on the pupillary border of the iris (see Figure 1). These are easily overlooked, especially in darkly pigmented irides, unless one maintains a high index of suspicion, and carefully examining the pupillary border of the iris under high magnification at the slit lamp before dilating the pupil, as this may obscure early peripupillary neovascularization. The new vessels then can be seen extending radially over the iris stroma in an irregular fashion (see Figure 2), unlike the normal iris vessels, which can be seen easily in elderly and lightly pigmented irides, the neovascular bundles grows over the iris stroma and is arranged in a meandering, less

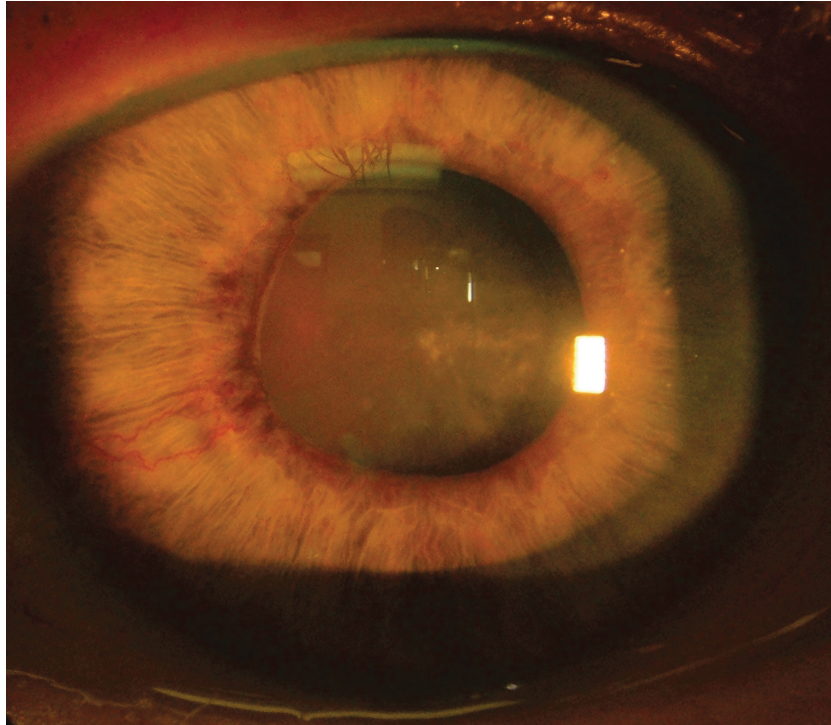


Figure 1. Slit-lamp view of iris in a patient with rubeosis iridis shows fine, tortuous vessels on the surface of the peripupillary iris, and 2 radially arranged new vessels extending towards the AC angle.

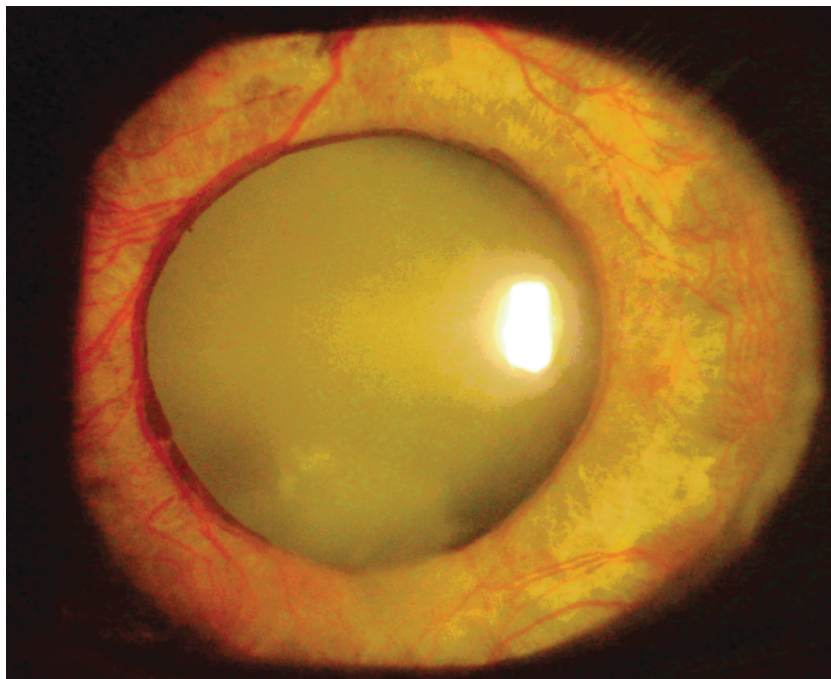


Figure 2. Slit-lamp view of iris in a patient with rubeosis iridis shows more advanced neovascularization with dilated, tortuous vessels on the surface iris, with early ectropion uvea and pupillary dilatation.

radial way. Growth of the new vessels along with their accompanying connective tissue, which contracts over time, explains the smooth iris surface, and attenuation of the iris pattern that can be noticed at this stage. Neovascularization eventually appears in the anterior chamber angle. Again this should be differentiated from the prominent vascular knuckles that can be normally seen on routine gonioscopy. The major point of difference, suggested by Chandler and Grant,⁴⁰ is that normal blood vessels remain behind the scleral spur; once a vessel is seen crossing the scleral spur and trabecular meshwork it should be considered abnormal.

Angle neovascularization is seen gonioscopically as single vascular trunks that grow from the peripheral iris across the scleral spur to the trabecular meshwork, where they arborize along the meshwork for a few clock hours like tree branches. In order not to miss early angle neovascularization, careful examination of the angle, with high magnification along with bright illumination, and minimal pressure on the goniolens is required to avoid blanching the new vessels. At this point, even though angle neovascularization is evident, the IOP may be unchanged until a significant portion of the trabecular meshwork is covered by the new vessels with their accompanying connective tissue. Although the iris neovascularization typically precedes the angle neovascularization, the reverse was reported too, justifying the need for careful gonioscopy when following patients for early evidence of anterior chamber neovascularization.

In the *open-angle stage* of NVG, both the iris and angle neovascularization have become much more prominent, and the IOP is elevated, often with reddish discoloration of the trabecular meshwork. The new vessels may cover the iris stroma from the pupillary margin to the iris root (see Figure 2) and may be associated with inflammation and hemorrhage, hence the old name congestive or hemorrhagic glaucoma. In the angle, the new vessels are more numerous, but the angle is still open. The fibrovascular membrane, which is invisible on gonioscopy, can block enough of the trabecular meshwork to impair the aqueous outflow leading to elevation of IOP.

Glaucomatous optic neuropathy may develop at this stage, due to elevation of IOP.

In the *angle-closure stage* of NVG, the fibrovascular membrane undergoes contracture. Peripheral anterior synechiae develop, due to membrane contraction, and then coalesce to close the anterior chamber angle like a zipper. Once angle closure occurs due to synchiae, the trabecular meshwork is permanently compromised. On the iris, this is seen clinically and histologically as flattening of the stroma, dragging the iris pigment epithelium through the pupil, causing ectropion uveae, pupillary dilation, and a forward displacement of the iris (see Figure 3). At such an advanced stage, the iris and angle neovascularization start to obliterate and vanish, and a smooth fibrovascular membrane along with a prominent Schwalbe's line can mimic a normal angle (pseudo-angle) (see Figure 4). The eye is typically painful and photophobic with poor

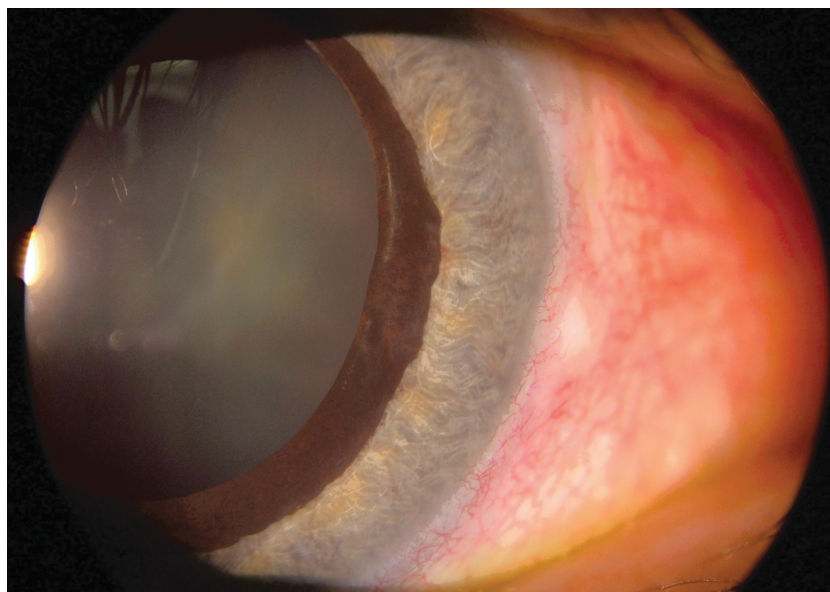


Figure 3. Slit-lamp view of a patient with the angle-closure stage of neovascular glaucoma shows numerous new vessels on the iris, with pupillary dilatation and ectropion uvea due to contracture of the fibrovascular membrane.

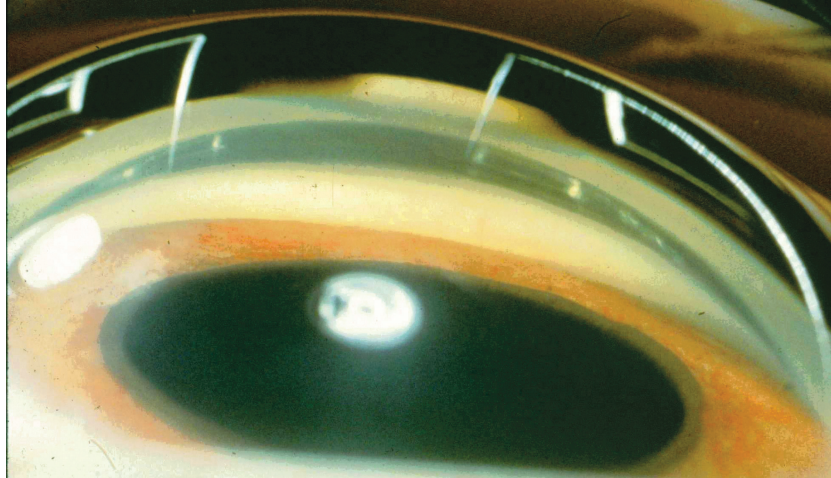


Figure 4. Gonioscopic view of a patient with the closed-angle stage of neovascular glaucoma shows intense neovascularization of the iris and a complete synchial closure of anterior chamber angle, with no visible angle structures.

vision. Moderate to marked conjunctival congestion is frequently associated with an edematous cornea, hyphema, and the IOP is usually remarkably high (see Figure 5).

Apart from this typical presentation, sometimes pain is mild or even absent, especially when IOP builds

up gradually. Vision could still be remarkably good if the cornea is clear and the underlying etiology didn't significantly affect the macula. The cornea can remain clear if the patient is young with healthy corneal endothelium and IOP was gradually raising. And IOP can be normal or even low at the end stage NVG, in such cases as carotid artery obstruction.

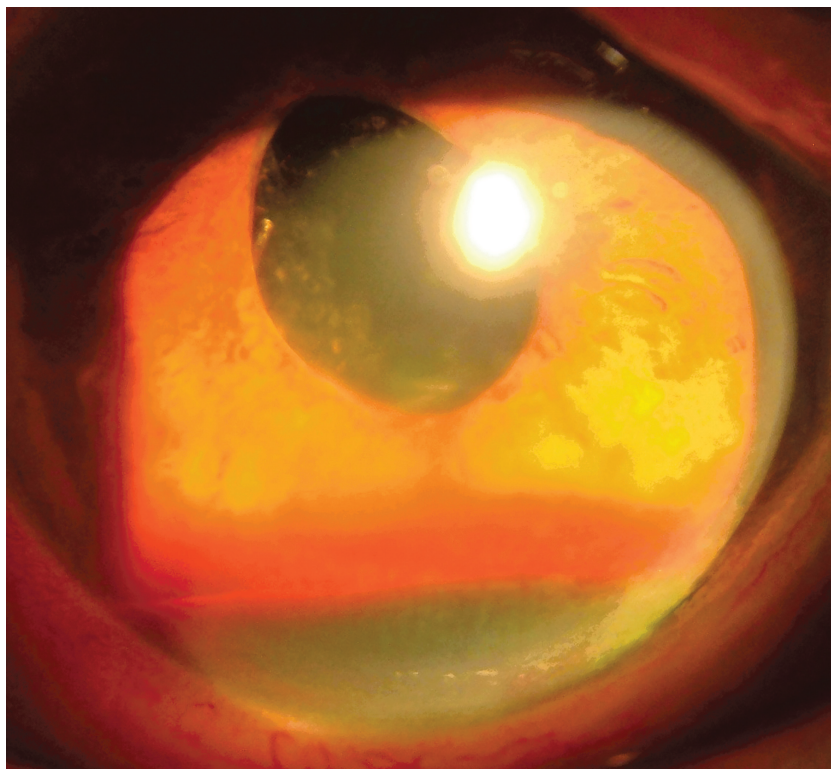


Figure 5. Slit-lamp appearance of the anterior segment of a patient with NVG shows rubeosis and hyphema.

DIFFERENTIAL DIAGNOSIS

Several ocular conditions with abnormally elevated IOP and prominent vessels can mimic NVG. The approach to manage those conditions is usually different from that required for NVG, mandating careful history taking and examination to exclude those other entities. The ocular conditions simulating NVG can be divided into:

Ocular Disorders with Engorged Iris Vessels

Those disorders are characterized by elevated IOP with engorgement and prominence of the normal stromal iris vessels.

Acute angle-closure glaucoma may be the most common condition confused with advanced NVG. Both may present with poor vision, highly elevated IOP, ciliary flush, and severe pain. In acute angle-closure glaucoma, engorged iris vessels may mimic the appearance of rubeosis iridis. Presence or absence of iris neovascularization is usually impossible due to the presence of corneal edema. If examination of the fellow eye also reveals a narrow occludable angle, then a diagnosis of primary angle closure is more likely. Also, pressure on gonioscopy (compression gonioscopy) may force the angle open. In NVG, the angle is sealed and cannot be forced open. Funduscopy exam in NVG is consistent with a hypoxic posterior segment.

Engorgement of iris vessels in patients with anterior uveitis, especially following intraocular surgeries, is commonly confused with NVG. After intraocular surgery, vessel dilatation secondary to intraocular inflammation and hypotony may occur, which might be confused with NVG in diabetic patients. In contrast with NVG, postsurgical dilatation of iris vessels usually resolves as the secondary uveitis is treated with topical corticosteroids, whereas neovascularization of the iris does not respond to such therapy.

Congenital iris tufts and prominent iris vessels in lightly pigmented irides may sometimes mimic neovascularization. Prominent iris vessels typically are radial, lie within the iris stroma, and, when in the chamber angle do not cross the scleral spur. In contrast, new vessels typically do not follow a radial course, lie on the surface of the iris, and may cross the scleral spur.

Retinopathy of prematurity may present with engorged iris vessels as a result of plus disease and concomitant angle-closure glaucoma from a retrolental membrane. Plus disease refers to arteriolar tortuosity and venous engorgement of the posterior pole and iris secondary to vascular shunting. Retinopathy of

prematurity is distinguished from NVG on the basis of characteristic fundus findings and the clinical setting.

Ocular Disorders with True Iris and Angle Neovascularization

Fuchs' heterochromic iridocyclitis may present with elevated IOP and iris neovascularization.⁴¹ Neovascularization secondary to iris ischemia could be found in the chamber angle as well as on the iris. The new vessels are thin and fragile and may result in a hyphema, either spontaneously or after paracentesis (Amsler's sign). This kind of glaucoma is not considered a genuine NVG in spite of the presence of neovascularization, as the elevation of IOP is due to uveitis intrinsic to the disease and not a result of the presence of new vessels. In addition progression to NVG is extremely rare.

Essential iris atrophy may present with elevated IOP associated with new vessel formation.⁴²

Very thin, nonprogressive iris NV can be found at the pupillary margin in pseudoexfoliation syndrome. The condition should be differentiated from NVG by the presence of the target lesion on anterior capsule and the absence of any retinal ischemic conditions.

Nonprogressive iris NV can also be seen in myotonic dystrophy, abnormal insulin secretion and elderly normal subjects.

Prognosis

NVG classically carries poor prognosis, typically ending up with severe loss of vision. Early diagnosis and prompt treatment with the new modalities of treatment can still save useful vision in patients with NVG. Visual loss in NVG is a common feature that may be attributed to severe ocular ischemia, glaucomatous optic nerve damage, cataract formation, corneal decompensation, recurrent hyphema with corneal blood staining, and phthisis bulbi. The most common cause of surgical failure in patients who have NVG is related to progression of the underlying retinal disease, not to uncontrolled IOP^{43,44} Patients who develop CRVO in one eye have a significant risk for developing CRVO in the other eye.⁷ A systemic disorder should be seriously considered in patients with bilateral CRVO.

In addition to the severe ocular morbidity, NVG is associated with high mortality rates, up to 22% and 15% as reported by Krupin et al.⁴⁴ and Mermoud et al.,⁴⁵ reflecting the fact that NVG is usually secondary to an advanced systemic disorder. The retinal ischemia and microangiopathy associated with proliferative diabetic retinopathy is usually part of systemic

advanced microangiopathy and tissue ischemia. The same applies to CRVO being associated with systemic arterial hypertension, atherosclerosis, and hypercoagulability status.

Follow-Up

Neovascularization of the iris has been reported to develop in 50% of patients who have proliferative diabetic retinopathy and in 60% of those who have the ischemic type of CRVO. NVG does not invariably follow the development of neovascularization of the iris. Once such neovascularization is detected, patients should be followed up carefully with repeated slit-lamp examinations and undilated gonioscopy.

The frequency of follow-up depends on the underlying etiology and the estimated risk of developing iris neovascularization. Follow-up schedules for patients with CRVO should be guided by visual acuity at presentation, as per the guidelines of the CRVO study group's report:

- 20/40 or better: every 1 to 2 months for the first 6 months;
- 20/50 or worse: every month for the first 6 months;
- worsening visual acuity: an ominous sign of progression to ischemic status.⁷

CONCLUSION

NVG is a potentially devastating ocular disorder where delayed diagnosis or inadequate treatment can result in loss of vision or, sometimes, loss of the globe itself. Early diagnosis of the disease with identification of the underlying cause, followed by immediate and aggressive treatment, is the key to better visual outcome. In managing NVG, it is essential to maintain a high index of suspicion in patients with predisposing posterior segment conditions. Early and aggressive treatment can preserve useful vision.

Declaration of Interest

The authors report no conflicts of interest. The authors alone are responsible for the content and writing of the paper.

REFERENCES

[1] Coats G. Further cases of thrombosis of the central vein. *Royal London Ophthalmic Hospital Report* 1906;16:516.
[2] Salus R. Rubeosis iridis diabetica, eine bischer unbekante diabetische Irisveränderung. *Med Klin* 1928;24:256.

[3] Kurz O. Zur rubeosis iridis diabetica. *Arch Augenheilkd* 1937;110:24.
[4] Weiss DI, Shaffer RN, Nehrenberg TR. Neovascular glaucoma complicating carotid-cavernous sinus fistula. *Arch Ophthalmol* 1963;69:304.
[5] Wand M. Neovascular glaucoma. In: Ritch RSM, Krupin T, eds., *The Glaucomas*, Vol 2. St. Louis: CV Mosby, 1996;1063–1110.
[6] Morrison JC, Pollack IP. *Glaucoma Science and Practice*. New York: Thieme, 2003.
[7] The Central Vein Occlusion Group. Natural history and clinical management of central retinal vein occlusion. *Arch Ophthalmol* 1997;115:486–491.
[8] Tasman W, Magargal LE, Augsburger JJ. Effects of argon laser photocoagulation on rubeosis iridis and angle neovascularization. *Ophthalmology* 1980;87:400.
[9] Magargal LE, Donoso LA, Sanborn GE. Retinal ischemia and risk of neovascularization following central retinal vein obstruction. *Ophthalmology* 1982;89:1241.
[10] Hayreh SS, Rojas P, Podhajsky P, et al. Ocular neovascularization with retinal vascular occlusion. III. Incidence of ocular neovascularization with retinal vein occlusion. *Ophthalmology* 1983;90:488.
[11] Margargal LE, Brown GC, Augsburger JJ, Donoso LA. Neovascular glaucoma following central retinal vein obstruction. *Ophthalmology* 1981;88:1095.
[12] Vannas A. Discussion of Bertelsen, I. The relationship between thrombosis in the retinal vein and primary glaucoma. *Acta Ophthalmol (Copenh)* 1961;39:603.
[13] Hoskins HD Jr. Neovascular glaucoma: Current concepts. *Trans Am Acad Ophthalmol Otol* 1974;78:330.
[14] Magargal LE, Brown GC, Augsburger JJ, et al. Neovascular glaucoma following branch retinal vein obstruction. *Glaucoma* 1981;3:333.
[15] Bonnet M, Jourdain M, Francoz-Taillanter N. Clinical correlation between rubeosis iridis and optic disc neovascularization. *J Fr Ophthalmol* 1981;4:405.
[16] Ohrt V. The frequency of rubeosis iridis in diabetic patients. *Acta Ophthalmol* 1971;49:301.
[17] Madsen PH. Rubeosis of the iris and haemorrhagic glaucoma in patients with proliferative diabetic retinopathy. *Br J Ophthalmol* 1971;55:368.
[18] Wright MM, Grajewski AL, Cristol SM, Parrish RK. 5-Fluorouracil after trabeculectomy and the iridocorneal endothelial syndrome. *Ophthalmology* 1991;98:314–316.
[19] Lanzl IM, Wilson RP, Dudley D, Augsburger JJ, Aslanides IM, Spaeth GL. Outcome of trabeculectomy with mitomycin-C in the iridocorneal endothelial syndrome. *Ophthalmology* 2000;107:295–297.
[20] Kim DK, Aslanides IM, Schmidt CM Jr, Spaeth GL, Wilson RP, Augsburger JJ. Long-term outcome of aqueous shunt surgery in ten patients with iridocorneal endothelial syndrome. *Ophthalmology* 1999; 106:1030–1034.
[21] Wand M. Neovascular glaucoma. In: Ritch R, Shields MB, Krupin T, eds, *The Glaucomas*. St. Louis: Mosby, 1996.
[22] Hayreh SS, Podhajsky P. Ocular neovascularization with retinal vascular occlusion. II. Occurrence in central and branch retinal artery occlusion. *Arch Ophthalmol* 1982;100:1585.
[23] Bresnick GH, Gay AJ. Rubeosis iridis associated with branch retinal arteriolar occlusions. *Arch Ophthalmol* 1967;77: 176.
[24] Brown GC, Magargal LE, Schachat A, et al. Neovascular glaucoma: Etiologic considerations. *Ophthalmology* 1984; 91: 315.
[25] Shields M. Bruce, Allingham R. Rand, Damji Karim F. et al. *Shields' Textbook of Glaucoma*, 5th Edition. Philadelphia, PA: Lippincott Williams & Wilkins, 2005.

- [26] Abedin S, Simmons RJ. Neovascular glaucoma in systemic occlusive vascular disease. *Ann Ophthalmol* 1982;14:284.
- [27] Coppeto J, Wand M, Bear L, Sciarra R. Neovascular glaucoma and carotid vascular occlusion. *Am J Ophthalmol* 1985;99:567.
- [28] Duker JS, Brown GC. Iris neovascularization associated with obstruction of the central retinal artery. *Ophthalmology* 1988;95:1244.
- [29] Sugar HS. Neovascular glaucoma after carotid-cavernous fistula formation. *Ann Ophthalmol* 1969; 11:1667.
- [30] Sugar HS. Neovascular glaucoma after carotid-cavernous fistula formation. *Am J Ophthalmol* 1979;11:667.
- [31] Harris GJ, Rice PR. Angle closure in carotid-cavernous fistula. *Ophthalmology* 1979;86:1521.
- [32] Brown GC, Magargal LE, Simeone FA, Goldberg RE, Federman JL, Benson WE. Arterial obstruction and ocular neovascularization. *Ophthalmology* 1982; 89:139.
- [33] Wand M. Neovascular glaucoma. In Ritch R, Shields MB, Krupin T, eds. *The Glaucomas*. St. Louis: Mosby, 1996.
- [34] Tanaka S, Ideta H, Yonemoto J, et al. Neovascularization of the iris in rhegmatogenous retina detachment. *Am J Ophthalmol* 1991;112:632.
- [35] Wilhelmus KR, Grierson I, Watson PG. Histopathologic and clinical associations of scleritis and glaucoma. *Am J Ophthalmol* 1981;91:697.
- [36] Yanoff M. Mechanisms of glaucoma in eyes with uveal melanoma. *Ophthalmol Clin* 1972;12:51.
- [37] Walton DS, Grant WM. Retinoblastoma and iris neovascularization. *Am J Ophthalmol* 1968;65:598.
- [38] Cappin JM. Malignant melanoma and rubeosis iridis. *Br J Ophthalmol* 1973;57:815.
- [39] Ritch R, Shields MB, Krupin T. *The Glaucomas Clinical Science*, 2nd edition. St. Louis, MO: Mosby, 1996.
- [40] Chandler PA, Grant W. *Lectures on Glaucoma*, Philadelphia: Lea and Febiger, 1965.
- [41] Perry HD, Yanoff M, Scheie NG. Rubeosis in Fuchs' heterochromic iridocyclitis. *Arch Ophthalmol*. 1975;93:337-339.
- [42] Jampol LM, Rosser MJ, Sears ML. Unusual aspects of progressive essential iris atrophy. *Am J Ophthalmol*. 1974;77: 353-357.
- [43] Tsai JC, Feuer WJ, Parrish RK II, Grajewski AL. 5-Fluorouracil filtering surgery and neovascular glaucoma. Long-term follow-up of the original study. *Ophthalmology*. 1995;102:887-893.
- [44] Sidoti PA, Dunphy TR, Baerveldt G, et al. Experience with the Baerveldt glaucoma implant in treating neovascular glaucoma. *Ophthalmology* 1995;102:1107-1118.
- [45] Krupin T, Kaufman P, Mandell AI, et al. Long-term results of valve implants in filtering surgery for eyes with neovascular glaucoma. *Am J Ophthalmol* 1983;95:775-782.