

**Concise Review: Limbal Stem Cell Deficiency, Dysfunction, and Distress**  
Sajjad Ahmad

*Stem Cells Trans Med* 2012, 1:110-115.

doi: 10.5966/sctm.2011-0037 originally published online January 26, 2012

The online version of this article, along with updated information and services, is  
located on the World Wide Web at:

<http://stemcellstm.alphamedpress.org/content/1/2/110>



## Concise Review: Limbal Stem Cell Deficiency, Dysfunction, and Distress

SAJJAD AHMAD

**Key Words.** Cornea • Corneal epithelium • Limbal stem cell • Limbal stem cell deficiency

### ABSTRACT

The cornea is the clear tissue at the front of the eye that transmits light to the retina at the back of the eye. The cornea is covered by an epithelium and surrounded by a narrow band of tissue known as the limbus. The limbus has two important roles in maintaining a healthy corneal epithelium. First, stem cells for the corneal epithelium reside at the limbus and not in the cornea. Second, the limbus acts as a barrier separating the clear avascular corneal epithelium from the surrounding vascular conjunctival tissue. A failure of these limbal functions can result in the painful and blinding disease of limbal stem cell deficiency. In this disease, the corneal epithelium cannot be maintained by the stem cells, and the corneal surface becomes replaced by hazy conjunctival tissue. There are many causes of limbal stem cell deficiency, such as burns to the eye, inflammatory diseases, and hereditary diseases. Current understanding of the pathophysiology of the disease is discussed here. In particular, understanding whether the limbal stem cells are lost or become dysfunctional or indeed whether the limbal microenvironment is disturbed is important when developing appropriate management strategies for the disease. *STEM CELLS TRANSLATIONAL MEDICINE 2012;1:110–115*

### INTRODUCTION

The cornea is a clear tissue that covers the front of the eye. Its main functions are to transmit and focus light to the back of the eye to enable visual perception. The cornea is composed of three main layers: an epithelium on the outer surface, a thick stroma, and an endothelium on the inner surface. The corneal epithelium is a stratified epithelium from which superficial terminal cells are naturally shed. The corneal epithelial cells lost are replaced by stem cells located at the peripheral edge of the cornea, in a region known as the limbus. The stem cells for the corneal epithelium are therefore more commonly known as limbal stem cells because of their anatomical location [1]. The limbus also acts as a physical barrier separating the clear cornea from the surrounding conjunctiva and its blood vessels that cover the white part of the eye (sclera).

### LIMBAL STEM CELLS

Evidence for the limbal location of corneal epithelial stem cells comes from almost 40 years of both clinical observations and basic science research. The migration of limbal pigment during corneal epithelial wound healing in guinea pig eyes first suggested the important role of the limbus with regard to the corneal epithelium [2]. This was confirmed by clinical observations in patients with corneal epithelial wounds, where it

was seen that the corneal epithelium healed from the peripheral aspects of the cornea [3]. Such observations led to the X, Y, Z hypothesis of corneal epithelial homeostasis, which suggested that the movement of cells from the basal layers of the corneal epithelium (X) and the movement of cells from the periphery of the cornea (Y) replace those cells that are lost from the corneal surface through natural shedding (Z) [4].

Basic science research has further localized the limbal stem cells to the basal layer of the limbal epithelium. DNA labeling studies of mouse corneas have identified a subset of epithelial cells in the basal layer of the limbal epithelium that move slowly through the cell cycle and in fact are often found in a quiescent state but that have the potential during wounding to cycle rapidly to replace the lost cells [5]. This quiescent yet agile potential to cell cycle is an important property of adult stem cells. Indeed, this potential can be seen during in vitro culture, where it has been shown that the limbus has a higher cell expansion potential than the cornea [6].

It is not surprising that corneal epithelial stem cells are found to reside in the basal layer of the limbus. The cellular microenvironment is important in maintaining the stem cell state of stem cells [7]. This is known as the stem cell niche. Limbal stem cells are no different from other adult stem cells in this respect. The basal layer of the limbus provides the stem cells closeness to stromal vasculature, which brings important

St. Paul's Eye Unit, Royal Liverpool University Hospital, Liverpool, United Kingdom

Correspondence: Sajjad Ahmad, FRCOphth, Ph.D., St. Paul's Eye Unit, Royal Liverpool University Hospital, Prescot Street, Liverpool, L7 8XP, United Kingdom. Telephone: 44-7834853610; e-mail: s2ahm@doctors.org.uk

Received October 11, 2011; accepted for publication December 14, 2011; first published online in *SCTM EXPRESS* January 26, 2012.

©AlphaMed Press  
1066-5099/2012/\$30.00/0

<http://dx.doi.org/10.5966/sctm.2011-0037>

growth factors to the stem cells [8]. The cornea, being a clear tissue, is avascular and so cannot provide this environment to its epithelial stem cells. In addition to vascular proximity, the limbal epithelial basal layer provides the stem cells close proximity to the limbal stromal fibroblasts, which again modify epithelial cell behavior. To increase the contact of limbal stem cells with their microenvironment, the basement membrane of the limbus undulates to increase the surface area. These undulations can be seen clinically on the surface of the limbus, giving it a corrugated appearance. These visible corrugations are referred to as the palisades of Vogt and are more prominent at the superior and inferior limbus where the upper and lower eyelids, respectively, provide protection to the limbal stem cells [2]. In addition to these undulations of the limbal basement membrane, over the past few years there has been increasing evidence that deeper epithelial ingrowths into the limbal stroma also exist. These have been termed limbal epithelial crypts, and it is postulated that in fact the true limbal stem cells actually reside in the depth of these crypts [9]. Limbal epithelial crypts are therefore putatively similar to intestinal crypts, where stem cells reside in the deep base of the crypt. As well as providing even closer proximity and increased contact with the limbal microenvironment, these deep ingrowths are also likely to have a protective role for the limbal stem cells [9].

There has been recent controversy regarding the possibility of corneal epithelial stem cells residing in the corneal epithelium, as well the limbal epithelium [10]. Despite this, there are many decades of both clinical and scientific evidence of the limbal location of the true corneal epithelial stem cell [11]. They have therefore more commonly come to be known as limbal stem cells.

#### THE CLINICAL DISEASE OF LIMBAL STEM CELL DEFICIENCY

Limbal stem cell deficiency is a disease in which the stem cell functions of the limbus and the barrier function of the limbus fail [12]. Because of failure of corneal epithelial healing from limbal stem cells, as a result of either loss or dysfunction, corneal epithelial defects appear and fail to heal normally. This results in chronic ocular surface discomfort and pain. In addition, limbal barrier failure results in the phenotypically different conjunctival epithelium, which surrounds the cornea and limbus, and its associated blood vessels to invade the corneal surface. This process of corneal conjunctivalization results in loss of corneal clarity and visual impairment. Limbal stem cell deficiency is therefore an extremely debilitating eye disease, being both painful and blinding.

There are many known causes of limbal stem cell deficiency, as well as some unknown or idiopathic cases [13, 14]. There are hereditary or genetic causes, such as aniridia, where there is a developmental dysgenesis of the anterior segment of the eye, including the limbus, among abnormalities of the rest of the eye [15]. There are acquired causes, including burns (both chemical and thermal) to the front of the eye. Inflammatory diseases of the front of the eye, including ocular cicatricial pemphigoid, Stevens-Johnson syndrome, and chronic limbitis, can also result in limbal stem cell deficiency. Contact lens-associated limbal stem cell deficiency has also been described [16]. This is caused either by toxicity of the contact lens solution or mechanical irritation and inflammation of the limbus as a result of contact lens friction. Extensive cryotherapy, radiation, or surgery of the limbus

can also result in limbal stem cell deficiency. The administration of subconjunctival or topical antiproliferative agents has also been known to impair corneal epithelial homeostasis, and in a small proportion of cases, it results in limbal stem cell deficiency [17].

The diagnosis of limbal stem cell deficiency is mainly made on clinical grounds [12]. Patient history and clinical observation of corneal conjunctivalization associated with persistent epithelial defects hints strongly at limbal stem cell deficiency. This can be confirmed by cytological analysis of cells from the superficial corneal epithelium. This is a technique known as corneal impression cytology [13, 18]. In brief, filter paper is placed on the surface of the patient's anesthetized cornea and removed. The superficial cells from the corneal surface that come away with the filter paper can then be analyzed cytologically. If the corneal impression is mainly acellular or contains normal corneal epithelial cells then it becomes less likely that limbal stem cell deficiency exists. However, if the impression consists of a mixture of corneal and conjunctival epithelial cells or mainly conjunctival epithelial cells then this is highly confirmative of limbal stem cell deficiency.

#### THE LOSS OF LIMBAL STEM CELLS

Like all other adult stem cell systems, such as the skin epidermis and the hematopoietic system, there are three main cell types of importance to the corneal epithelium: the stem cell, the transient amplifying cell, and the terminally differentiated cell [1, 19]. The limbal stem cells are few in number, and in a state of health they remain relatively quiescent, with the potential to divide and multiply rapidly in a state of wounding. The transient amplifying cells are greater in number and are more active during health, with their main function being to replace lost or shed corneal epithelial cells. They have the capacity to divide or amplify exponentially during wounding. They are present in the limbus and peripheral corneal epithelium, most likely in the basal epithelial layers. The terminally differentiated cells of the corneal epithelium form the bulk of the corneal epithelium, and they are the main functioning epithelial cells of the cornea. They are present mainly in the superficial layers of the corneal epithelium. Being terminal, they have no capacity to divide or multiply and are eliminated from the tissue compartment by natural shedding. The corneal epithelium is therefore composed of a pyramid structure of cells, where there are few stem cells at the top of the pyramid, there are a greater but still relatively small number of the transient amplifying cells in the middle of the pyramid, and the majority of the base of the pyramid is formed by a large number of terminally differentiated cells.

By definition, the term "limbal stem cell deficiency" implies that this condition results from a reduction in the number of limbal stem cells present for corneal epithelial maintenance. As there are no specific markers to identify limbal stem cells, it is not really possible to determine the number of stem cells maintaining the corneal epithelium. However, there are some indirect means by which to estimate this number. Colony forming efficiency is an *in vitro* assay that can determine the proportion of cells present that can give rise to epithelial colonies in culture [20]. This often varies considerably from 1% to 20% of cells from the limbal epithelium. Side population analysis is a flow cytometric method used to identify cells that have stem cell properties.

This has been used to enrich for a stem cells from the hematopoietic system, neural stem cells, and indeed also limbal stem cells [21]. This method enriches rather than purifies or isolates the stem cells. It has been estimated that less than 1% of the total proportion of limbal epithelial cells fall within the side population [22]. Using a series of mouse chimera experiments, it has been estimated that the corneal epithelial cells present on the mouse cornea arise from fewer than 100 cells at the limbus [23, 24]. This suggests that certainly in the mouse cornea there are fewer than 100 limbal stem cells present. Histological analysis of the human limbus has identified the presence of approximately six limbal epithelial crypts [9]. If each crypt contains one or a few true limbal stem cells, then it can certainly be concluded that the human corneal epithelium is maintained by a very small number of stem cells. When all the evidence is taken together, although we cannot quantify the number of human limbal stem cells, it can certainly be said that the number is much less than 1% of the whole limbal epithelial population.

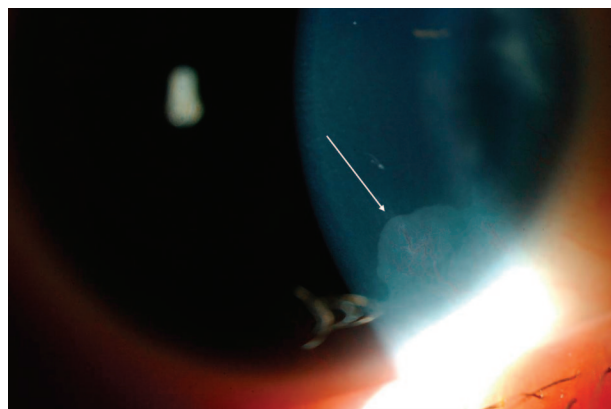
Limbal stem cells are present in the basal layers of the limbal epithelium at least, if not in much deeper ingrowths or crypts of the limbal epithelium. It would therefore take a significantly deep penetrating external injury (such as an alkali chemical burn, thermal burn, cryogenic burn, or radiation) or an internal injury (such as inflammation directed from the limbal microenvironment) to damage the limbal stem cells. Indeed, this notion is supported by studies in rabbits, which show that removal of the basal layers of the limbal epithelium is essential for conjunctivalization of the corneal surface and hence limbal stem cell deficiency [25]. As it is likely that there are few true limbal stem cells present around the limbal circumference anyway, it is not inconceivable that a small focal but significant injury could result in a segment of the corneal epithelium from healing normally (focal limbal stem cell deficiency). Obviously, a more diffuse injury affecting the whole limbal circumference deeply would result in a total limbal stem cell deficiency.

As it is likely that the normal corneal epithelium is supported by a few limbal stem cells, it is not surprising that the cornea is prone to conjunctivalization by single-hit injuries, such as chemical burns. It would not take the loss of many of these limbal stem cells to result in abnormal or delayed corneal epithelial healing. The conjunctiva would take advantage of this and encroach onto the corneal surface, resulting in the clinical signs of limbal stem cell deficiency.

#### THE DYSFUNCTION OF LIMBAL STEM CELLS

If the numbers of limbal stem cells are small, it is also possible that a small but significant alteration in their normal function or indeed a small change in their microenvironment could precipitate signs of limbal stem cell deficiency. The most understood of these mechanisms is in aniridia [15]. Mutations in *PAX6*, a gene required for normal oculo-genesis, result in the clinical disease of aniridia. One of the hallmarks of aniridia is a keratopathy. Aniridia-related keratopathy, as it is most commonly known, occurs as a result of peripheral and progressive conjunctivalization of the corneal surface, that is, a form of limbal stem cell deficiency (Fig. 1). This is characteristically not present at birth but manifests itself from mid to late childhood and onward.

Most of our understanding of aniridia comes from studying the eyes of *PAX6* heterozygote mice [26]. By investigating the keratopathy in these mice, several important mechanisms have



**Figure 1.** Early limbal stem cell deficiency in a patient with aniridia. A frond of conjunctival epithelium with a blood vessel (indicated by the white arrow) can be seen encroaching beyond the limbus and onto the peripheral cornea.

been determined. Cytokeratin 12 is an intermediate filament protein present within the normal corneal epithelium. It has been shown that *PAX6* expression is essential for upregulation of cytokeratin 12. Matrix metalloproteinases are a group of zinc-containing degradative enzymes. The corneal extracellular matrices undergo constant slow remodeling during health, and this process relies on matrix metalloproteinases. The mouse model of aniridia shows that matrix metalloproteinase 9 expression is deficient, and this results in stromal inflammation and corneal vascularization. Cell adhesion molecules offer anchorage to surrounding cells and to the extracellular matrix. *PAX6* is known to regulate the expression of cell adhesion molecules. Indeed, the mouse model of aniridia shows that there are enlarged intercellular spaces and impaired epithelial cell migration.

Findings in the *PAX6* heterozygote mouse model correlate with the clinical signs seen in aniridia-related keratopathy. The limbal stem cell deficiency seen in aniridia therefore results both from a limbal stem cell dysfunction and from an abnormal limbal stem cell microenvironment. These changes in the microenvironment may result in further limbal stem cell dysfunction or indeed in limbal stem cell destruction.

#### LIMBAL TISSUE TRANSPLANTATION AND LIMBAL EPITHELIAL CELL THERAPY FOR LIMBAL STEM CELL DEFICIENCY

If limbal stem cell loss or dysfunction is the main cause of limbal stem cell deficiency, then its definitive treatment requires the replacement of healthy limbal stem cells. This is done by transplanting healthy limbal tissue, either from the patient's other eye if it is healthy (limbal autograft) or from the eye of a living or cadaveric donor (limbal allograft), to the eye with limbal stem cell deficiency after removing the conjunctival tissue from the corneal surface [27, 28].

More contemporary management involves the transplantation of ex vivo expanded limbal epithelial cells [29, 30]. This technique involves taking a small biopsy or explant from the patient's other eye if it is healthy (autoexplant) or from the healthy eye of a living or cadaveric donor (alloexplant). Then, either the explant is used intact for culture or the limbal epithelial cells are digested from the explant to produce a cell suspension. The explant or suspension is then cultured for a period of time either on inactivated 3T3 mouse fibroblasts or on human amniotic membrane

[31]. The overall result is the expansion of limbal epithelial cells, including the stem cells. The resulting cultured limbal epithelial sheet is then transplanted to the eye with limbal stem cell deficiency after the conjunctival tissue is removed from the corneal surface.

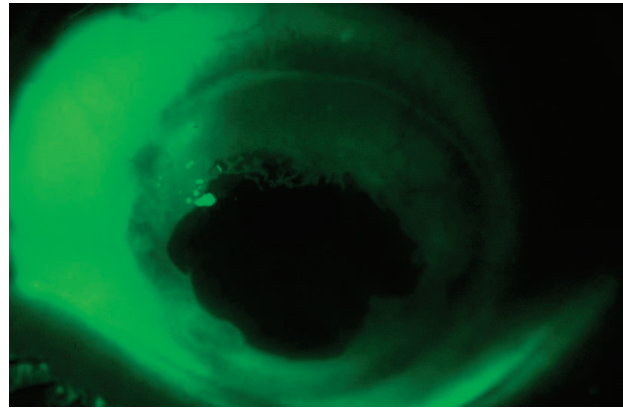
Whole limbal tissue transplantation and *ex vivo* expanded limbal epithelial cell transplantation are the definitive methods for normalizing corneal epithelial homeostasis. Short-term results certainly show these procedures to be effective. Long-term results, however, can vary considerably [32, 33]. Allogeneic tissue or cell transplants do less well in the longer term, and it is likely that immune rejection plays a significant role in this [34]. In addition, patient selection is important in maintaining long-term success. An understanding of the etiology of limbal stem cell deficiency in each patient, taking into consideration possible impacts on limbal stem cell numbers and the microenvironment, is therefore essential in identifying an effective treatment modality.

#### THE FATE OF DONOR CELLS IN ALLOGENEIC LIMBAL EPITHELIAL TISSUE AND CELL TRANSPLANTS

From studies, it is unclear how limbal tissue or cell transplantation normalizes the corneal epithelium. It is unlikely that restoration of limbal stem cell number alone is the cause, as there are likely to be so few true stem cells present. In addition, loss of limbal stem cell numbers is not the only cause of limbal stem cell deficiency. As has been mentioned previously, there is currently no means of identifying the limbal stem cells directly, but we can identify their progeny. This is done by removing and analyzing the superficial corneal epithelial cells using corneal impression cytology. In allotransplantation of either whole limbal tissue or cultured limbal epithelial cells, the donor and recipient are obviously different. This genetic difference can be used to study the origin of superficial corneal epithelial cells after allotransplantation using DNA fingerprinting techniques [35].

Allotransplantation provides us with an ideal opportunity to study the fate of donor cells. The donor origin of superficial corneal epithelial cells following both limbal tissue and cultured limbal epithelial transplantation has been investigated and analyzed at different stages post-transplant. DNA fingerprinting of recipient corneal impression cytology samples 3–5 years after whole limbal tissue allotransplantation, even when the procedure provides long-term reversal of the limbal stem cell deficiency and clinical normalization of the corneal epithelium, shows that the superficial corneal epithelial cells have recipient rather than donor origin [36]. In another study, using mechanical scraping to remove superficial corneal epithelial cells rather than corneal impressions and analyzing both X and Y chromosomes in the opposite-sex allografts, as well as of human leukocyte antigen (HLA) origin, it has been suggested that in most patients there is a spectrum of cell origin [37]. Cells can be 100% of donor origin, 100% of recipient origin, or a mixture of the two. Superficial corneal epithelial cell sampling by impression cytology has also been performed in patients undergoing cultured limbal epithelial allograft procedures. In this study, of the patients who had corneal epithelial normalization, there were none who showed cell origin from the donor after 9 months [38].

The results from all these studies can be difficult to interpret, as the cases described are a mixture of different types of limbal stem cell deficiency, with different causes for the disease. How-



**Figure 2.** Complete peripheral corneal conjunctivalization with a clear central corneal epithelium. The surface of the eye was stained with fluorescein. Delayed staining (in green) highlights the conjunctival epithelium, which can be seen encroaching onto the peripheral corneal surface around the whole circumference of the cornea. Despite this, the central corneal epithelium remained normal.

ever, it is clear that in some patients, the corneal epithelial cells do not originate from the donor after a period of time. It is also possible that in the longer term, beyond the time scales analyzed in these studies, this finding is universal. Indeed, the original cause of the limbal stem cell deficiency may well be important in determining the long-term fate and role of the transplant, whether this is whole limbal tissue or cultured epithelium.

#### LIMBAL STEM CELL DISTRESS

The limbus is a region where two epithelial cell populations meet, namely the corneal and conjunctival epithelia. The proliferative potential generated at the limbus by limbal stem cells prevents the conjunctival epithelium from encroaching past the limbus. However, when there is a reduction in the number of limbal stem cells or if there is dysfunction as a result of intrinsic cellular abnormality or microenvironmental changes, the proliferative potential of limbal stem cells is less than that of the conjunctival epithelium, and conjunctivalization of the corneal surface ensues. Alternatively, overproliferation of the conjunctival epithelium with a normal proliferative potential of the limbal stem cells (for example, in the clinical condition of pterygium) may also result in corneal conjunctivalization.

Other than limbal stem cell loss or dysfunction, there may be an alternative or additional explanation for conjunctivalization of the corneal surface. The limbal stem cells might find themselves in a state of distress where an acute injury or insult, for example, temporarily prevents the stem cells from proliferating. The conjunctival epithelium then takes advantage of this and crosses past the limbus and onto the corneal surface. There are three main reasons for hypothesizing this concept of transient limbal stem cell distress.

#### Rabbit Studies

Rabbit studies show that if the superficial layers of the limbal epithelium are removed chemically while maintaining an intact basal limbal epithelial layer containing limbal stem cells, then corneal conjunctivalization still occurs [25]. This situation therefore occurs in an environment of normal number, functioning, and environment of limbal stem cells, but where the limbal stem cells fail to proliferate quickly enough.

### A Subgroup of Patients with Limbal Stem Cell Deficiency

A small group of patients with limbal stem cell deficiency have peripheral corneal conjunctivalization with a longstanding normal central corneal epithelium [39] (Fig. 2). This status quo between the conjunctival and corneal epithelial proliferative potential can often be maintained for many years. There are two possible explanations for these clinical signs. Either the limbal stem cells have migrated centrally onto the cornea, or the stem cells in their limbal location have at some stage temporarily failed, resulting in encroachment of the superficial but not the deep limbal barrier.

### Donor Cell Origin Studies in Allotransplantation

In allotransplantation for limbal stem cell deficiency, the corneal epithelium regains its recipient origin after a period of time after the transplant. There are only two explanations for this. Either there were always enough host limbal stem cells present but they had temporarily been distressed and failed to proliferate, or the limbal transplant provided cytokines and environment for a reduced number of host limbal stem cells to self-renew.

### CONCLUSION

Limbal stem cell deficiency is a disease characterized by abnormal corneal epithelial maintenance that results in conjunctivalization of the corneal surface. There are many pathophysiological reasons for limbal stem cell deficiency. These include a true loss of limbal stem cells (such as in chemical burns to the eye), a dysfunction of the limbal stem cells (as probably occurs in aniridia), an alteration of the limbal stem cell microenvironment (as occurs in limbal inflammation), or indeed a transient disruption of limbal stem cell proliferation, that is, a state of limbal stem cell distress (as most likely occurs after a burn injury to the limbus). A better understanding of the processes that result in limbal stem cell deficiency is important so that more targeted management strategies can be used.

### DISCLOSURE OF POTENTIAL CONFLICTS OF INTEREST

The authors indicate no potential conflicts of interest.

### REFERENCES

- Ahmad S, Figueiredo F, Lako M. Corneal epithelial stem cells: Characterization, culture and transplantation. *Regen Med* 2006;1:29–44.
- Davanger M, Evensen A. Role of the pericorneal papillary structure in renewal of corneal epithelium. *Nature* 1971;229:560–561.
- Dua HS, Gomes JA, Singh A. Corneal epithelial wound healing. *Br J Ophthalmol* 1994;78:401–408.
- Thoft RA, Friend J. The X, Y, Z hypothesis of corneal epithelial maintenance. *Invest Ophthalmol Vis Sci* 1983;24:1442–1443.
- Cotsarelis G, Cheng SZ, Dong G et al. Existence of slow-cycling limbal epithelial basal cells that can be preferentially stimulated to proliferate: Implications on epithelial stem cells. *Cell* 1989;57:201–209.
- Ebato B, Friend J, Thoft RA. Comparison of limbal and peripheral human corneal epithelium in tissue culture. *Invest Ophthalmol Vis Sci* 1988;29:1533–1537.
- Schofield R. The stem cell system. *Biomed Pharmacother* 1983;37:375–380.
- Gipson IK. The epithelial basement membrane zone of the limbus. *Eye (Lond)* 1989;3:132–140.
- Dua HS, Shanmuganathan VA, Powell-Richards AO et al. Limbal epithelial crypts: A novel anatomical structure and a putative limbal stem cell niche. *Br J Ophthalmol* 2005;89:529–532.
- Majo F, Rochat A, Nicolas M et al. Oligopotent stem cells are distributed throughout the mammalian ocular surface. *Nature* 2008;456:250–254.
- Sun TT, Tseng SC, Lavker RM. Location of corneal epithelial stem cells. *Nature* 2010;463:E10–E11.
- Ahmad S, Osei-Bempong C, Dana R et al. The culture and transplantation of human limbal stem cells. *J Cell Physiol* 2010;225:15–19.
- Puangsrichareon V, Tseng SC. Cytologic evidence of corneal diseases with limbal stem cell deficiency. *Ophthalmology* 1995;102:1476–1485.
- Espana EM, Grueterich M, Romano AC et al. Idiopathic limbal stem cell deficiency. *Ophthalmology* 2002;109:2004–2010.
- Ramaesh K, Ramaesh T, Dutton GN et al. Evolving concepts on the pathogenic mechanisms of aniridia related keratopathy. *Int J Biochem Cell Biol* 2005;37:547–557.
- Clinch TE, Goins KM, Cobo LM. Treatment of contact lens-related ocular surface disorders with autologous conjunctival transplantation. *Ophthalmology* 1992;99:634–638.
- Lichtinger A, Pe'er J, Frucht-Pery J et al. Limbal stem cell deficiency after topical mitomycin C therapy for primary acquired melanosis with atypia. *Ophthalmology* 2010;117:431–437.
- Dart J. Impression cytology of the ocular surface: Research tool or routine clinical investigation? *Br J Ophthalmol* 1997;81:930.
- Hall PA, Watt FM. Stem cells: The generation and maintenance of cellular diversity. *Development* 1989;106:619–633.
- Pellegrini G, Golisano O, Paterna P et al. Location and clonal analysis of stem cells and their differentiated progeny in the human ocular surface. *J Cell Biol* 1999;145:769–782.
- de Paiva CS, Chen Z, Corrales RM et al. ABCG2 transporter identifies a population of clonogenic human limbal epithelial cells. *STEM CELLS* 2005;23:63–73.
- Budak MT, Alpdogan OS, Zhou M et al. Ocular surface epithelia contain ABCG2-dependent side population cells exhibiting features associated with stem cells. *J Cell Sci* 2005;118:1715–1724.
- Mort RL, Ramaesh T, Kleinjan DA et al. Mosaic analysis of stem cell function and wound healing in the mouse corneal epithelium. *BMC Dev Biol* 2009;9:4.
- Collinson JM, Chanas SA, Hill RE et al. Corneal development, limbal stem cell function, and corneal epithelial cell migration in the Pax6(+/-) mouse. *Invest Ophthalmol Vis Sci* 2004;45:1101–1108.
- Chen JJ, Tseng SC. Abnormal corneal epithelial wound healing in partial-thickness removal of limbal epithelium. *Invest Ophthalmol Vis Sci* 1991;32:2219–2233.
- Ramaesh T, Collinson JM, Ramaesh K et al. Corneal abnormalities in Pax6+/- small eye mice mimic human aniridia-related keratopathy. *Invest Ophthalmol Vis Sci* 2003;44:1871–1878.
- Holland EJ. Epithelial transplantation for the management of severe ocular surface disease. *Trans Am Ophthalmol Soc* 1996;94:677–743.
- Kenyon KR, Tseng SC. Limbal autograft transplantation for ocular surface disorders. *Ophthalmology* 1989;96:709–722; discussion 722–723.
- Pellegrini G, Traverso CE, Franzi AT et al. Long-term restoration of damaged corneal surfaces with autologous cultivated corneal epithelium. *Lancet* 1997;349:990–993.
- Tsai RJ, Li LM, Chen JK. Reconstruction of damaged corneas by transplantation of autologous limbal epithelial cells. *N Engl J Med* 2000;343:86–93.
- Osei-Bempong C, Henein C, Ahmad S. Culture conditions for primary human limbal epithelial cells. *Regen Med* 2009;4:461–470.
- Baylis O, Figueiredo F, Henein C et al. 13 years of cultured limbal epithelial cell therapy: A review of the outcomes. *J Cell Biochem* 2011;112:993–1002.
- Shortt AJ, Secker GA, Notara MD et al. Transplantation of ex vivo cultured limbal epithelial stem cells: A review of techniques and clinical results. *Surv Ophthalmol* 2007;52:483–502.
- Rao SK, Rajagopal R, Sitalakshmi G et al. Limbal allografting from related live donors for corneal surface reconstruction. *Ophthalmology* 1999;106:822–828.
- Henderson TR, Findlay I, Matthews PL et al. Identifying the origin of single corneal cells by DNA fingerprinting: Part I: Implications for corneal limbal allografting. *Cornea* 2001;20:400–403.

**36** Henderson TR, Findlay I, Matthews PL et al. Identifying the origin of single corneal cells by DNA fingerprinting: Part II: Application to limbal allografting. *Cornea* 2001;20:404–407.

**37** Shimazaki J, Kaido M, Shinozaki N et al.

Evidence of long-term survival of donor-derived cells after limbal allograft transplantation. *Invest Ophthalmol Vis Sci* 1999;40:1664–1668.

**38** Daya SM, Watson A, Sharpe JR et al. Outcomes and DNA analysis of ex vivo expanded

stem cell allograft for ocular surface reconstruction. *Ophthalmology* 2005;112:470–477.

**39** Dua HS, Miri A, Alomar T et al. The role of limbal stem cells in corneal epithelial maintenance: Testing the dogma. *Ophthalmology* 2009;116:856–863.

This article has been cited by 1 HighWire-hosted articles:  
<http://stemcellstm.alphamedpress.org/content/1/2/110#otherarticles>