



# A new approach to the classification of neonatal corneal opacities

Ken K. Nischal<sup>a,b</sup>

## Purpose of review

Neonatal corneal opacification (NCO) describes the loss of corneal transparency at or soon after (<4 weeks) birth. Historically, the literature is strewn with terminology that has been at best misleading and at worst, a hindrance to selecting the appropriate treatment plan for, accurate genotype-phenotype correlation of and a better understanding of the entities that present in the clinic.

## Recent findings

Recent literature has demonstrated that certain terms such as 'sclerocornea' are unhelpful when alluding to total NCO. The term Peters anomaly has also become a 'waste paper basket' diagnosis for anterior segment developmental anomalies. A new classification of NCO is suggested by the author, which allows a better understanding of the cause of NCO and the likely prognosis of therapeutic intervention.

## Summary

This classification system should help the clinician understand the cause of NCO, better explain this to parents and recognize those conditions in which therapeutic intervention may be helpful. By understanding which conditions have a better chance of interventional success and by employing outcome definitions that take into consideration the developing neurobiological system of the infant brain and the effects of vision on its development, it is hoped more children with NCO will attain useful visual function.

## Keywords

classification, corneal opacification, neonatal, Peters anomaly, sclerocornea

## INTRODUCTION

Terminology for congenital neonatal corneal opacification (NCO) may be confusing [1,2<sup>a</sup>,3]. NCO occurs with a prevalence of six in 100 000 newborns in Europe [4]. Understanding the exact genetic causes of NCO has resulted in some controversy in part due to unclear terminology such as 'sclerocornea with Peters anomaly' [5]. This issue of phenotyping is crucial if we are to progress in our understanding of the heterogeneous genetic causes of NCO, which frequently causes blindness from birth, and may be associated with other anterior segment developmental anomalies of the eye.

Traditionally the differential diagnosis for NCO is remembered by the mnemonic 'S.T.U.M.P.E.D' (Sclerocornea, Tears in Descemet's membrane, Ulcers, Metabolic, Peters, Endothelial dystrophy and Dermoid). Although this serves as an aid to help the clinicians think of a differential diagnosis, it does not help define phenotype accurately.

In a recent review of chromosomal abnormalities causing congenital corneal opacification [2<sup>a</sup>], the authors found that of the 28 articles in which the

term 'sclerocornea' was used, it described cornea plana/peripheral scleralization in 13 articles, whereas in the remaining 15 it signified total corneal opacification regardless of the cause. Similarly, in four of the 17 articles in which the term 'Peters anomaly' was used, it described a complete corneal opacity, without sonographic or histologic evidence of iridocorneal or keratolenticular adhesions. Ocular ultrasonography was used to better describe the phenotype in only four articles and ultrasound biomicroscopy (UBM) in only one [2<sup>a</sup>]. This suggests that a new classification/terminology may be worth considering helping with better genotype-phenotype

<sup>a</sup>Children's Eye Center, Children's Hospital of Pittsburgh of UPMC, Pittsburgh, Pennsylvania, USA and <sup>b</sup>University of Pittsburgh, Pittsburgh, Pennsylvania, USA

Correspondence to Ken K. Nischal, MD, FRCOPhth, Children's Hospital of Pittsburgh, 4401 Penn Avenue, Suite 8000, Pittsburgh, PA 15224, USA. E-mail: nischalkk@upmc.edu

**Curr Opin Ophthalmol** 2012, 23:344–354

DOI:10.1097/ICU.0b013e328356893d

## KEY POINTS

- Terminology in the area of neonatal corneal opacification is confusing. This article proposes a clearer classification system for neonatal corneal opacity.
- Peters anomaly is a generally descriptive term that fails to identify specific clinical features that have ramifications for prognosis.
- The term sclerocornea applied to a total congenital corneal opacification is incorrect and should be avoided. Rather more specific terminology is proposed.
- Neonatal corneal opacification should be considered in terms of primary and secondary diseases, which may be congenital or acquired.
- The decision to intervene surgically, and the procedure that will afford the best outcome, can best be determined with a clear understanding of the cause of the corneal opacity.

correlation studies and better assessment of prognosis with or without intervention.

NCO may be considered in terms of primary and secondary corneal disease.

## PRIMARY CORNEAL DISEASE

By definition, these forms of neonatal corneal opacities are always present at birth and never acquired thereafter. Primary congenital causes of corneal opacification include corneal dystrophies, corneal dermoid, peripheral sclerocornea and a recent description of CYP1B1 cytopathy.

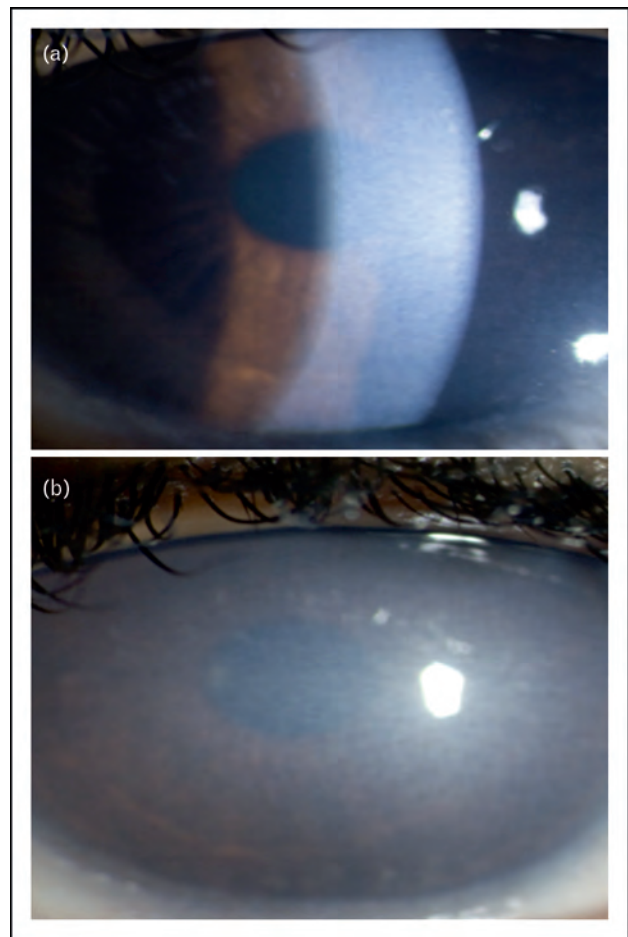
### Corneal dystrophies

Four corneal dystrophies may present at birth, which are as follows:

#### Congenital hereditary endothelial dystrophy

Congenital hereditary endothelial dystrophy (CHED) may be inherited in an autosomal recessive (CHED 2) or autosomal dominant (CHED 1) manner [6–8,9<sup>\*\*\*</sup>].

CHED is characterized by diffuse corneal edema and thickening of Descemet's membrane affecting both eyes usually symmetrically presenting at birth [6]. The corneal edema can vary from a blue gray ground glass appearance to total corneal opacification (Fig. 1a and b). The clinical features remain stationary or progress slowly depending on the form of inheritance. CHED 1 is autosomal dominant and



**FIGURE 1.** (a) Slit lamp photo of a 4-year-old boy with congenital hereditary endothelial dystrophy (CHED 2). Note the ground glass appearance of the corneal opacification. (b) A 7-year-old boy with CHED 1.

CHED 2 autosomal recessive. Patients with CHED 1 have clear corneas at birth and corneal clouding is first noted during the first or second year and is slowly progressive up to 5–10 years of age. Photophobia and epiphora are common, whereas nystagmus is uncommon. In contrast, corneal clouding is present at birth or within the neonatal period in CHED 2. Corneal opacification is dense at the time of diagnosis, and does not tend to progress [7]. There is no associated photophobia or epiphora. Nystagmus is invariably present early, presumably the result of severe corneal opacification at an early age [7] Vision tends to be better in autosomal dominant form than in recessive, but the visual acuity is usually severely affected

The pathogenesis of CHED is considered to be due to a primary dysfunction of the corneal endothelium characterized by increase permeability and an abnormal Descemet's membrane secretion [8]. Mutations in SLC4A11 have been shown to cause

some cases of CHED 2 [9<sup>\*\*\*</sup>]. Although the gene responsible for CHED 1 is unknown, its locus is 20p11.2–q11.2, which is the same region as the gene for posterior polymorphous dystrophy.

Histological features of CHED include diffuse epithelial and stromal edema, defects in the Bowman membrane, paucity of endothelial cells, multinucleated cells and a thickened Descemet's membrane, reflecting an abnormal secretion by the endothelial cells [8].

Reports of CHED with glaucoma are published [11], but caution is also raised about the possibility of artefactually raised pressure readings due to the very thick corneas seen in these cases [12]. Ancillary signs of congenital glaucoma must be looked for to make the correct diagnosis (e.g. increased horizontal corneal diameter, Haab striae, buphthalmos).

As CHED is a primary corneal disease, it is not surprising that most reports of penetrating keratoplasty (PKP) in the literature report relatively good graft survival and outcomes, although amblyopia due to marked early visual deprivation remains a problem [13,14]. More recently, reports of 'Descemet's stripping automated endothelial keratoplasty' and 'Descemet's stripping endothelial keratoplasty' have been published and the early reports are promising in terms of graft survival outcome and visual rehabilitation [15<sup>\*\*</sup>].

### Posterior polymorphous corneal dystrophy

Although posterior polymorphous corneal dystrophy (PPCD) usually presents in the second decade of life, it does rarely present at birth. It is characterized by polymorphous opacities at the endothelial level with or without the 'snail track' sign. It is associated with an increased risk of developing glaucoma and histologically is typified by multilayering of the endothelium, which develops epithelial characteristics that are readily detected by positive staining for cytokeratin [16].

Rarely it presents at birth [1,9<sup>\*\*\*</sup>] when congenital glaucoma is often the differential diagnosis, but a normal corneal diameter for age, and absence of buphthalmos and Haab striae, helps steer the clinician to the diagnosis of a corneal endothelial dystrophy. The definitive diagnosis is histological. Family history or positive examination identifying an affected parent is also helpful. PPCD is inherited in an autosomal dominant manner. Mutations in multiple genes have been associated with PPCD.

Case series limited to congenital PPCD are non-existent, but it is the author's experience and that of the pediatric case series published [1] that being a primary corneal disease, the outcomes of PKP are reasonably good even in children and infants.

### Congenital hereditary stromal dystrophy

Congenital hereditary stromal dystrophy, also known as congenital stromal corneal dystrophy may be caused by a mutation in the decorin (*DCN*) gene at 12q22. There is diffuse clouding limbus to limbus, with flake-like opacities in the stroma. There is no vascularization or staining of the cornea [9<sup>\*\*\*</sup>]. Reports of good outcomes are published wherein deep anterior lamellar keratoplasty (DALK) has been performed [10].

### X-linked endothelial corneal dystrophy

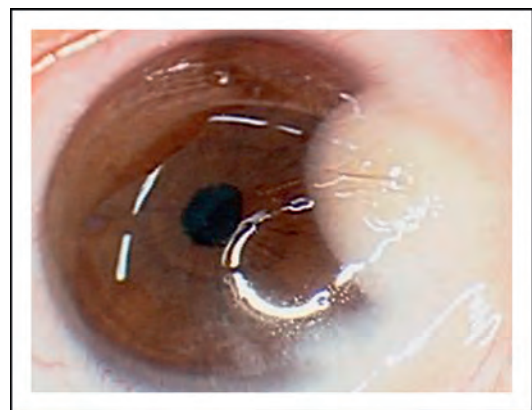
X-linked endothelial corneal dystrophy was recently described in one pedigree [17]. In the only infant affected, corneal transplant was not necessary but it was thought that with time the endothelial dystrophy worsened, necessitating intervention. Again the report suggests good outcome of PKP in an adult. The infant presented with corneal haze, which was not superficial and which improved some days and worsened others.

### Corneal dermoid

Corneal dermoids are choristomas. The majority is epibulbar (Fig. 2), but they may also be corneal and obstruct the visual axis. Lamellar keratoplasty is well described for even large corneal dermoids encroaching the visual axis, with good outcomes [18]. More extensive lesions with secondary iris change and/or lens change PKP has also been described [19]. Outcomes of lamellar keratoplasty are reasonably good, even though postoperative astigmatism can still lead to amblyopic visual loss.

### Peripheral sclerocornea

The most important terminology change that would improve our understanding of NCO is the



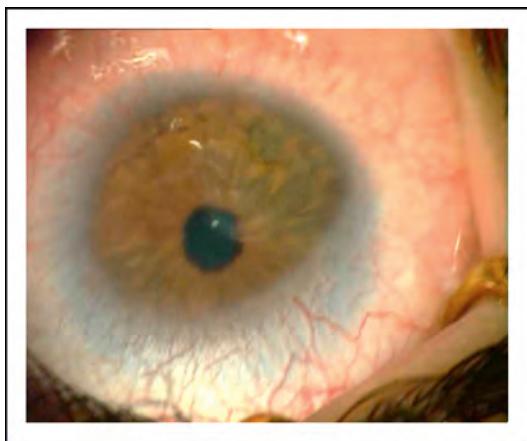
**FIGURE 2.** Dermoid that does not encroach on the visual axis. Note the hair growing from the dermoid.

banishment of the term 'sclerocornea' when describing total corneal opacification. Using the word 'sclerocornea' to describe total congenital corneal opacification has been shown to be incorrect by imaging techniques on several occasions [1,2<sup>a</sup>], and has also been shown to be confusing [2<sup>a</sup>,5].

Interestingly, the two entries in *OMIM* termed 'sclerocornea' (dominant 181700 *OMIM*; recessive 269400 *OMIM*) are based on citations from 1985 and 1965, with the first describing a pedigree with peripheral sclerocornea and not total corneal opacification [20,21]. The only condition in which this term should apply is peripheral sclerocornea or cornea plana (CNA) (*CNA1*, *OMIM* 121400, autosomal dominant; *CNA2*, *OMIM* 217300, autosomal recessive). In this condition, there is a flat cornea with reduced radius of curvature (lowest in *CNA2*), peripheral scleralization and often stromal opacities with or without irido-corneal adhesions, although these latter are more commonly seen in *CNA2* (Fig. 3). This condition needs accurate refraction and spectacle or contact lens visual rehabilitation. Glaucoma is often a secondary problem due to shallow anterior chamber.

### CYP1B1 cytopathy

Mutations in *CYP1B1* are the commonest genetic cause for primary congenital glaucoma. In a recent article [22], it has been shown that some cases of congenital glaucoma can be accompanied by a congenital corneal opacification that is not due to the raised intraocular pressure. This entity presents as an opacity that fails to clear despite prompt and early control of intraocular pressure. Histological evaluation does not show features of CHED or stromal scarring consistent with neglected glaucoma.



**FIGURE 3.** Peripheral sclerocornea with cornea plana. This should be the only entity with which the term 'sclerocornea' is used.

Whether this entity should be considered a dystrophy is debatable. It meets the criteria for a dystrophy: clinical phenotype (ground-glass opacification from limbus to limbus); histology (loss of Bowman's membrane in the central cornea with infiltration of stromal cells but not in the periphery, absence of endothelial cells and loss of Descemet's membrane centrally with marked thinning and marked reduction of endothelial cells peripherally but without any iridocorneal or kerato-lenticular adhesions); and identified gene mutation (*CYP1B1*). This study also raises the possibility that this entity is what was originally described as von Hippel's ulcer.

The report shows good graft survival, but a severe optic neuropathy secondary to relentless glaucoma.

## SECONDARY CORNEAL DISEASE

This may be congenital or acquired.

### Congenital

Secondary corneal disease presenting at birth is invariably due to a maldevelopment of the anterior segment of the eye and includes:

#### Kerato-irido-lenticular dysgenesis

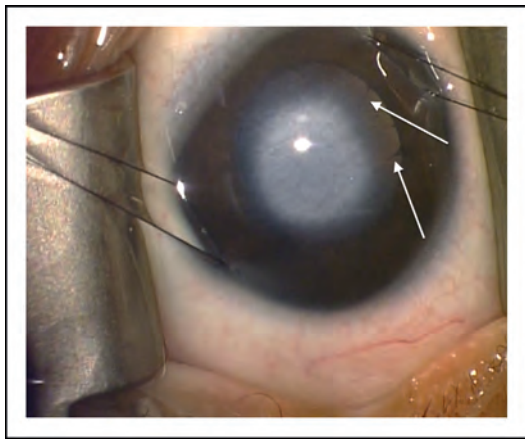
This includes iridocorneal adhesions, failure of the lens separation from the cornea, lens separation but failure thereafter of lens development, lens separation and formation but later apposition to the cornea and, lastly, failure of lens to form altogether.

##### *Iridocorneal adhesions.*

The phenotype here may be central (Fig. 4) or eccentric (Fig. 5) or, less commonly, a total corneal opacity. These malformations have traditionally been called Peters anomaly type 1, but the most important clinical feature for purely iridocorneal adhesions is that the corneal opacity is invariably avascular. Zaidman [23] has shown that results of PKP are good and a recent review of the literature supports this finding [24]. Why iridocorneal adhesions should occur is unknown, but they have been seen with mutations in *PITX2*, *FOXC1*, *CYP1B1*, *PAX6* and other genes [25–27].

##### *Lens fails to separate from cornea.*

The phenotype is usually a vascularized central or total corneal opacity (Fig. 6). This is traditionally called Peters anomaly type 2. In this condition, there is a kerato-lenticular adhesion due to a developmental failure of separation of the invaginating lens vesicle from the overlying surface ectoderm. On

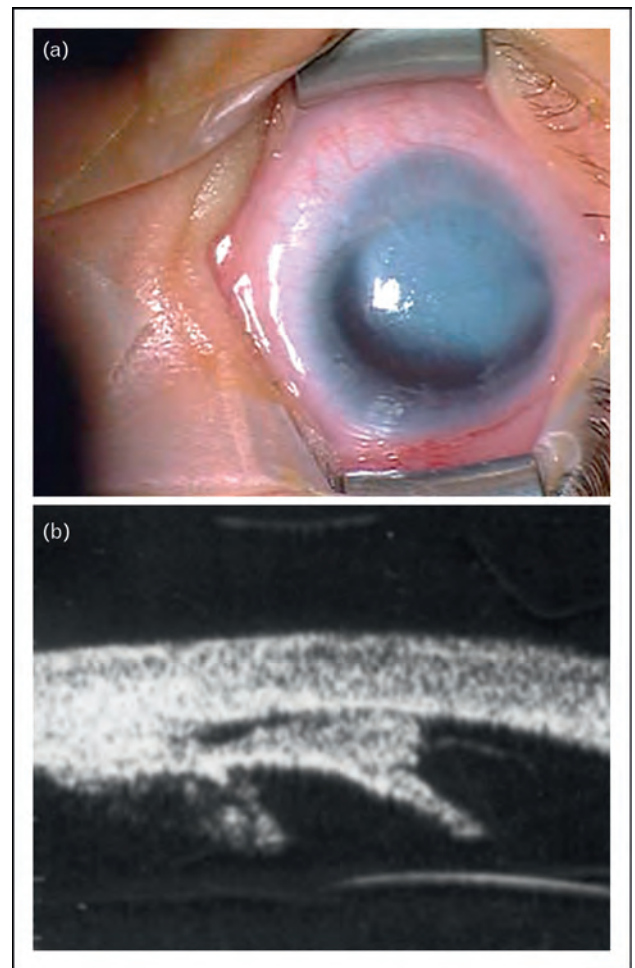


**FIGURE 4.** Central avascular corneal opacity associated with iridocorneal adhesions but no lens involvement (traditionally called Peters anomaly type 1). Patient is about to undergo an optical iridectomy that was preferred here because child was from a developing country where follow-up for corneal transplant could not be guaranteed. The iridocorneal adhesions are seen extending from the edge of the pupil (white arrows).

high-frequency ultrasound (or UBM), the anterior lens capsule is not discernible at the point of attachment and the lens is often cataractous. In a mouse model [28], homozygous mutations in the gene *foxe3* result in developmental failure of lens vesicle–ectoderm separation. *Foxe3* is thought to be essential for closure of the lens vesicle and is a factor that promotes survival and proliferation in the lens epithelium [29]. Mutations in *FOXE3* in humans have been described, with homozygous mutations causing primary aphakia [30] (see below) and heterozygous mutations causing a variable phenotype including ‘Peters anomaly’ [31]. Not all cases of failed lens–ectoderm separation are due to *FOXE3* mutations (Fig. 6), but it is apparent that a primary lens problem can lead to extralenticular changes including corneal opacification. It is not surprising then that corneal transplants for such cases often result in early rejection due to the lens having to be removed at the time of surgery with subsequent exposure of the vitreous to the new donor graft [24].

*Lens separates but fails to form thereafter.*

The phenotype here is usually total corneal opacification with vascularization (Fig. 7). This can only be diagnosed by anterior segment imaging using high-frequency ultrasound or anterior segment ocular coherence tomography (Fig. 7). The prognosis for corneal transplantation is poor due to the need for concomitant vitrectomy at the time of surgery, as there is only ever lens remnant. Whether the vitreous itself is abnormal in such cases is unclear.

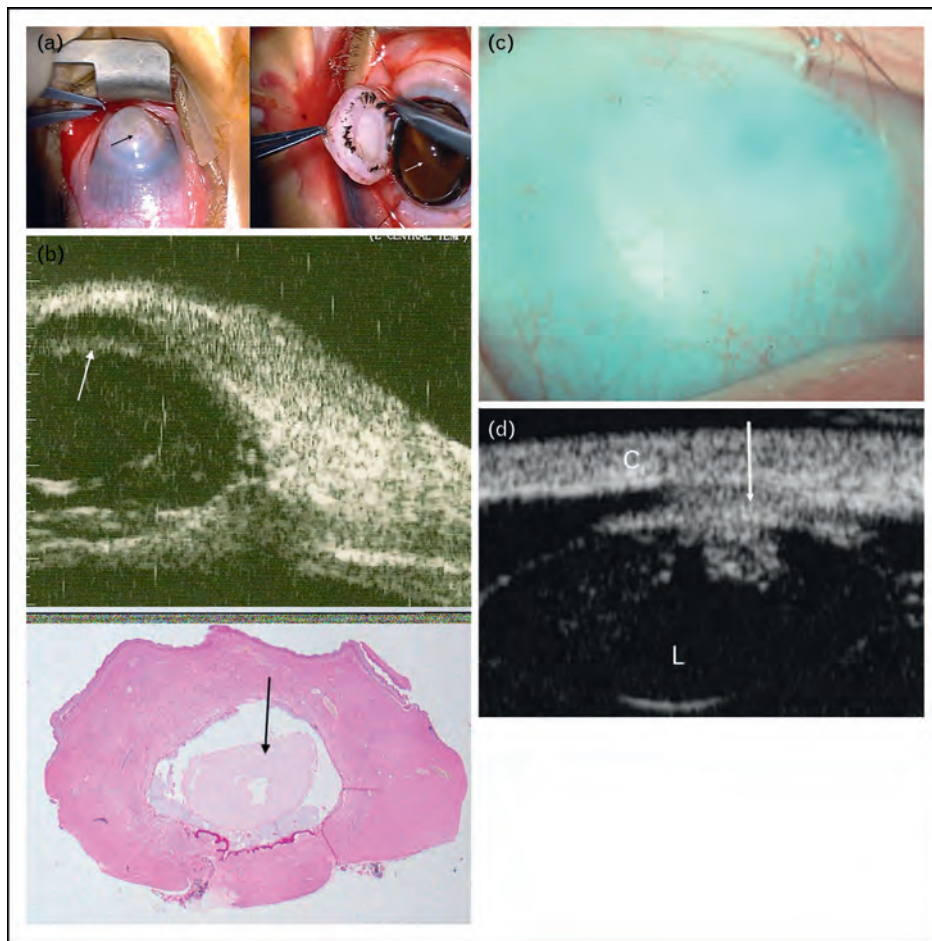


**FIGURE 5.** (a) Clinical picture of an eccentric avascular corneal opacity, which is due to iridocorneal adhesions as shown by the ultrasound biomicroscopy (b).

*Lens separates and forms, but there is late corneal apposition.*

Here there is often a central white opacity that is usually avascular. The clue to it ‘not’ being a failure of separation is the finding of an intact anterior capsule reflectivity on high-frequency ultrasound (Fig. 8). Surgical removal of the lens is the most effective treatment here, allowing recovery of the endothelium rather than primary corneal transplantation. Note, removal of the lens without peeling off the anterior capsule that is adherent to the cornea often leads to maximal clearance of the corneal opacity. Causes include the following:

- (1) Hypoxia: why exactly this should happen is unclear, but it has been reported [32] and also seen by the author.
- (2) Persistent fetal vasculature: called by some authors pseudo-Peters anomaly; occurs most likely due to retrolenticular membrane pushing



**FIGURE 6.** Central vascularized corneal opacity (panel a left, black arrow). At corneal transplantation, no lens is seen (panel a right, white arrow pointing to vitreous). The ultrasound biomicroscopy was mistakenly interpreted as showing a lens close to the cornea (panel b top, white arrow), but histology showed that the lens had failed to separate from the cornea at all (panel b bottom, black arrow showing lens embedded in cornea). Another case of vascularized total corneal opacification; this should not be called 'sclerocornea' (c). Note the anterior capsule of the lens is not discernible, suggesting that there was incomplete separation of lens from cornea (panel d, white arrow). C, cornea; L, lens.

lens forward to the cornea (Fig. 9); and it may be seen also in vitreoretinal dysplasias [33].

- (3) Aniridia: this may be entirely due to a very shallow anterior chamber and the slightest kerato-lenticular touch (Fig. 10) [34].

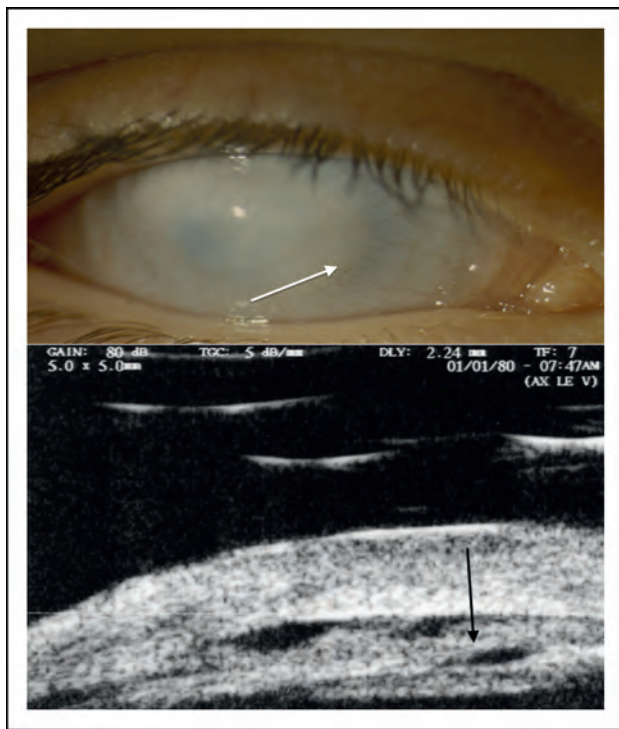#### *Lens fails to form.*

This is best described as primary aphakia. It is distinct from resorption of a lens once it is fully formed as may be seen, for example in the membranous cataracts of Hallermann–Streiff syndrome. Primary aphakia is a rare condition that can be recognized by an opaque cornea, which will still allow transillumination of light. The eyes may be microphthalmic. The key clinical features are a silver/grey appearance to the cornea (Fig. 11). This condition has been shown to be due to homozygous or compound heterozygous mutations in *FOXE3*

[30,31]. This is a primary lens defect with secondary corneal opacification. Zinn [35], almost 40 years ago, showed that removal of the chick embryo lens resulted in an opaque, thin cornea, presumably because factors are released by the developing lens that promote normal corneal growth. Outcomes of PKP for this condition are very poor, often with phthisis of the eye within weeks of surgery. These cases often develop glaucoma and the natural history is that untreated they will often spontaneously rupture [36]. Retinal dysplasia may also be found.

#### **Irido-trabecular dysgenesis**

This group of disorders essentially includes primary congenital glaucoma and other entities in which glaucoma and abnormal irides are found together with corneal opacities.



**FIGURE 7.** Total corneal opacity with some fine vessels (white arrow). Ultrasound biomicroscopy shows lens separate but not properly formed (black arrow).

*Primary congenital glaucoma.*

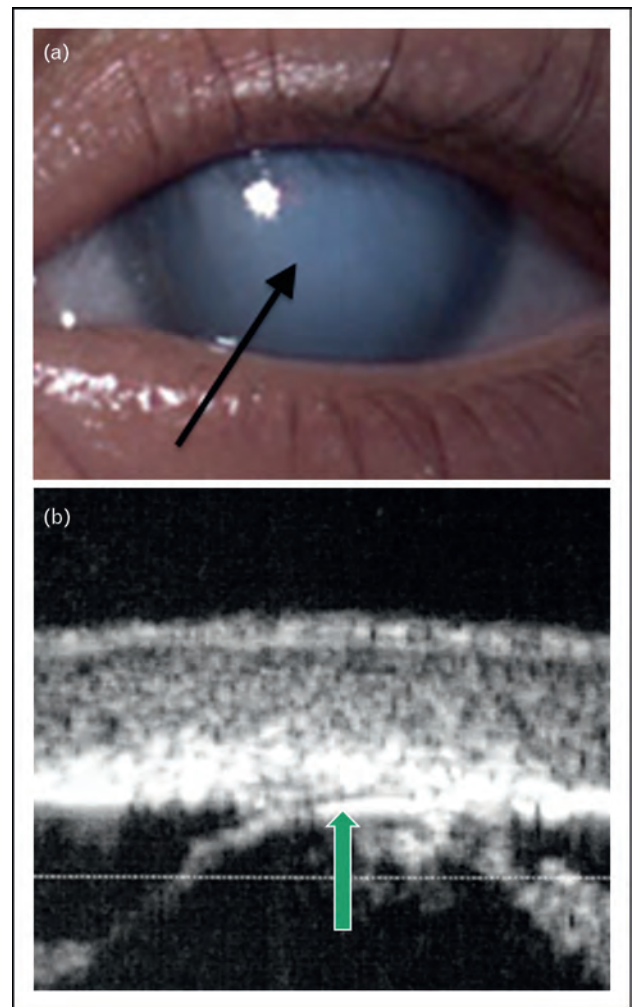
Most commonly caused by mutations in *CYP11B1* [37], mutations in *LTBP2* [38] have also been implicated in this disease. Treating the glaucoma causes reversal of the secondary corneal opacification (Fig. 12), but if the condition is neglected then permanent stromal scarring accompanied by breaks in Descemet's membrane may be seen.

*Intracorneal cyst.*

This phenotype has been described in case reports [39] and recently digenic inheritance described in a single case [40<sup>\*</sup>]. The mechanism is unknown, but usually glaucoma is a severe problem. There is what appears at first to be relative clearing in the center of the opacity suggestive of corneal clarity, but actually this is because of a thinned anterior stroma at the position of the intrastromal cyst (Fig. 13). Prognosis for surgery depends on associated ocular signs and features. The graft tends to remain clear, but retinal detachment has been described due to posterior persistent fetal vasculature [40<sup>\*</sup>].

**ACQUIRED**

This includes infection, trauma and metabolic causes.



**FIGURE 8.** The child was born prematurely and mother was adamant that the central and avascular opacity of the cornea (black arrow) was not present at birth but developed over a few weeks (a). Note also the ultrasound biomicroscopy that clearly shows an anterior capsular reflectivity (green arrow), suggesting that the lens separated and then later became apposed to the cornea (b).

**Infection**

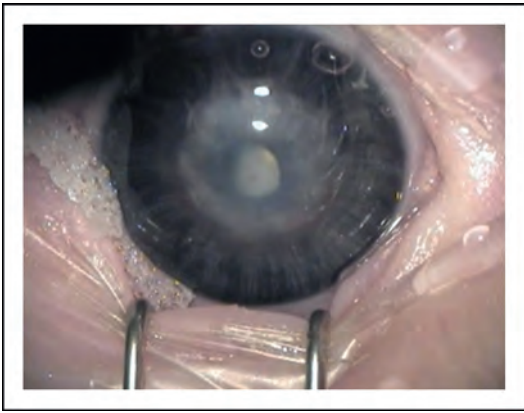
The commonest, but not the only causes, are viral and bacterial. In some parts of the world, fungal infections have been described in infants less than 4 weeks old.

**Viral**

The commonest cause is herpes simplex virus.

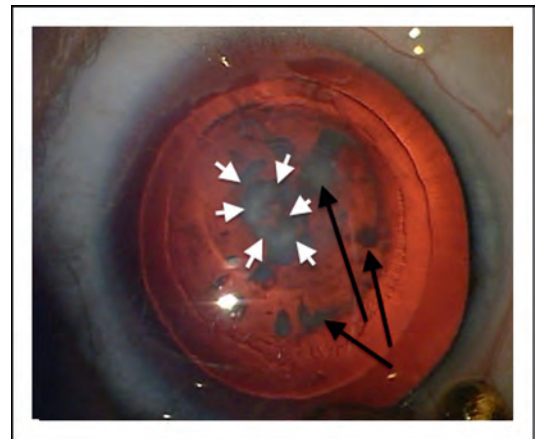
*Herpes simplex virus.*

This is one of the most common viral infections to affect the cornea in newborns [41,42]. Onset is often within 2 weeks of birth and so not strictly congenital. The presentation is of a cloudy cornea with a large epithelial defect (Fig. 14). Diagnosis is



**FIGURE 9.** The child has a corneal opacity secondary to persistent hyperplastic primary vitreous (PHPV), causing the lens to be pushed forward and up against the cornea. (Courtesy of Dr Jan Teerjd de Faber.)

often delayed, as congenital glaucoma is often considered first, but the lack of increased corneal diameter, raised intraocular pressure or buphthalmos should raise the suspicion of another cause. Corneal scrapes for virology are essential. Systemic pediatric evaluation is critical to exclude pneumonitis, hepatitis and/or encephalitis. Treatment with

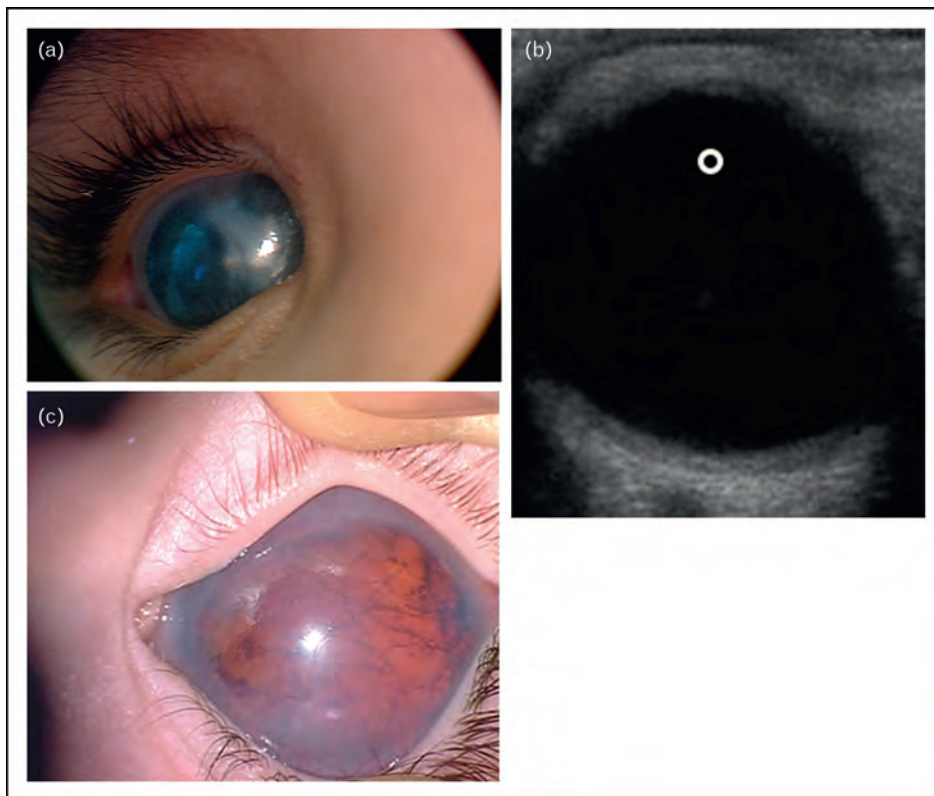


**FIGURE 10.** Child with aniridia and keratolenticular touch, causing the lens opacities and also a corneal opacity. White arrows show the corneal opacity and the black arrows the lens opacities.

PKP should not be performed in the acute phase of the disease. Even later, there is an increased risk of recurrence in the graft.

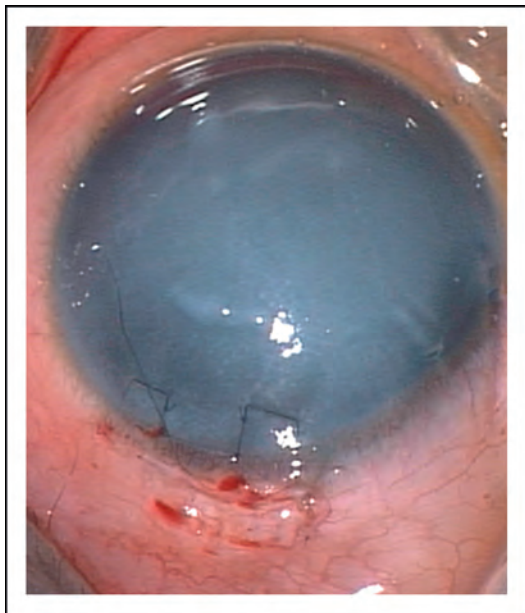
#### **Bacterial**

Bacterial infection can result in significant corneal opacities [43–45] (Fig. 15) and, although PKP should



**FIGURE 11.** The child has primary aphakia. Note the silver/grey appearance of the cornea (a). Lack of a lens is shown on the ultrasound scan (white circle shows area where lens echo should be seen but it is absent) (b). The stroma is so thin that a red reflex can still be seen in some cases (c).





**FIGURE 12.** Corneal opacity secondary to glaucoma. The picture is taken just after completion of combined trabeculectomy–trabeculotomy. Corneal clarity after control of congenital glaucoma can take several weeks.


be considered, if the scarring is not full thickness, deep anterior lamellar keratoplasty [46] can be successfully performed. *Neisseria gonorrhoea* should be considered in all cases of purulent keratoconjunctivitis.

**Trauma**

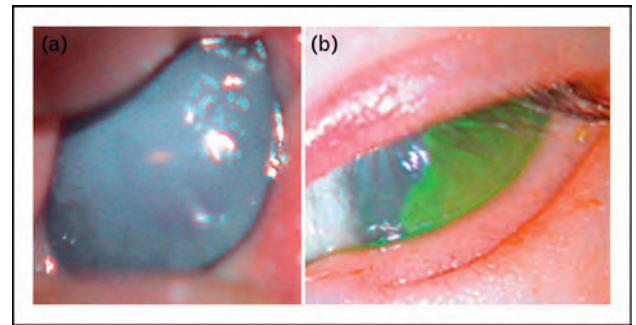
Although any form of trauma, including postnatal covert (blunt injury or medical child abuse) or overt accidental injury, can cause corneal opacification, specific causes that should be kept in mind when a child presents at birth with a corneal opacity include forceps injury and amniocentesis injury.

**Forceps injury**

Corneal edema secondary to forceps injury during complicated childbirth is well recognized. The



**FIGURE 13.** Intracorneal cyst seen clinically and by ultrasound biomicroscopy showing thinning centrally overlying the cyst (\*). The arrow is pointing to a preserved posterior corneal layer.



**FIGURE 14.** Neonate with herpes simplex virus (HSV) keratitis (a). After a few days of topical and systemic antivirals, note the reduction in epithelial defect (b).

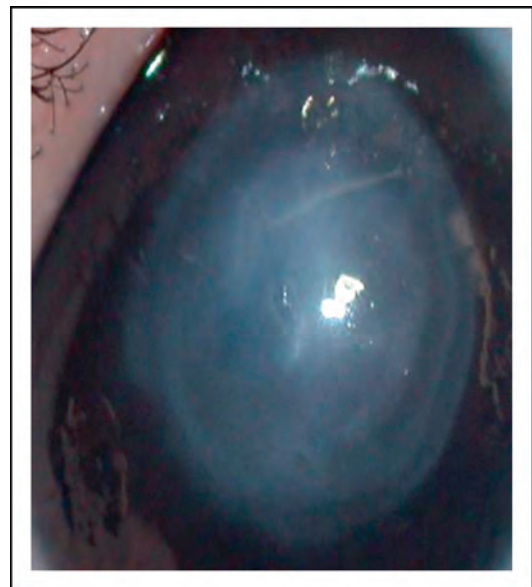breaks seen are usually linear and almost always unilateral. Recently the use of Descemet’s stripping automated endothelial keratoplasty has been advocated even as late as 8 years of age with improvement in visual acuity [47].

**Amniocentesis injury**

This is extremely rare but should be borne in mind when dealing with a unilateral presentation in which the opacity looks very angular or linear commensurate with a needle perforation. Concomitant signs such as cataract, iris or pupil abnormalities, or lid damage should raise the suspicion.

**Metabolic**

Although many textbooks will list mucopolysaccharidoses, cystinosis and other metabolic disorders



**FIGURE 15.** Child with healed infectious keratitis. This child had a successful deep anterior lamellar keratoplasty, as the scar tissue was not full thickness.

as causes of corneal clouding in newborns, there is only one condition that truly causes this at birth or within 2–3 weeks thereafter.

### Mucopolidosis IV

This is the only metabolic condition that can present within a few weeks of birth [48]. It is extremely rare and the patient will often have other systemic abnormalities due to severe psychomotor delay causing the child to be hospitalized.

### CONCLUSION

There have been many reports of outcomes of pediatric keratoplasty in children. Most of these reports fail to delineate the diagnosis accurately using anterior segment imaging [49–52]. By adopting the proposed mechanism of classification, it is hoped that a better understanding of prognosis is attained, a better understanding of cause is achieved and, therefore, a better possible outcome realized. Most studies also concentrate on corneal clarity as a measure of success, but the functional vision attained, even if only 20/400, has a much larger effect on global development than the clinical ophthalmologist may imagine [53<sup>■</sup>,54].

### Acknowledgements

Figure 9 courtesy of Jan-Tjeerd de Faber (MD), Ophthalmic Surgeon, The Rotterdam Eye Hospital, 180 Schiedamse Vest Rotterdam 3011 BH, The Netherlands.

### Conflicts of interest

The author is funded by National Institutes of Health CORE Grant P30 EY008098, Eye and Ear Foundation of Pittsburgh, Pennsylvania, USA and an unrestricted grant from Research to Prevent Blindness, New York, New York, USA.

There are no conflicts of interest.

### REFERENCES AND RECOMMENDED READING

Papers of particular interest, published within the annual period of review, have been highlighted as:

- of special interest
- of outstanding interest

Additional references related to this topic can also be found in the Current World Literature section in this issue (p. 451).

1. Nischal KK, Naor J, Jay V, *et al*. Clinicopathological correlation of congenital corneal opacification using ultrasound biomicroscopy. *Br J Ophthalmol* 2002; 86:62–69.
2. Mataftsi A, Islam L, Kelberman D, *et al*. Chromosome abnormalities and the genetics of congenital corneal opacification. *Mol Vis* 2011; 17:1624–1640. The authors review all the published chromosomal abnormalities reported with congenital corneal opacification. This paper is a useful reference when dealing with children with chromosomal abnormalities.
3. Nischal KK. Congenital corneal opacities: a surgical approach to nomenclature and classification. *Eye* 2007; 21:1326–1337.
4. Bermejo E, Martinez-Frias ML. Congenital eye malformations: clinical epidemiological analysis of 1 124 654 consecutive births in Spain. *Am J Med Genet* 1998; 75:497–504.
5. Bleyen I, Bartels MC, Wolfs RC. Newborn with bilateral hazy corneas. *Bull Soc Belge Ophthalmol* 2007; 303:29–32.
6. Toma NMG, Ebenezer ND, Inglehearn CF, *et al*. Linkage of congenital hereditary endothelial dystrophy to chromosome 20. *Hum Mol Genet* 1995; 4:2395–2398.
7. Judisch GF, Maumenee IH. Clinical differentiation of recessive congenital hereditary endothelial dystrophy and dominant hereditary endothelial dystrophy. *Am J Ophthalmol* 1978; 85:606–612.
8. Ehlers N, Modis L, Moller-Pedersen T. A morphological and functional study of congenital hereditary endothelial dystrophy. *Acta Ophthalmol Scand* 1998; 76:314–318.
9. Weiss JS, Møller HU, Lisch W, *et al*. The IC3D classification of the corneal dystrophies. *Cornea* 2008; 27 (Suppl 2):S1–S83. Although not published within the last year, this is a landmark article in developing a better classification for corneal dystrophies with excellent illustrations. A must read for all ophthalmologists.
10. Kim JH, Ko JM, Lee I, *et al*. A novel mutation of the decorin gene identified in a Korean family with congenital hereditary stromal dystrophy. *Cornea* 2011; 30:1473–1477.
11. Ramamurthy B, Sachdeva V, Mandal AK, *et al*. Coexistent congenital hereditary endothelial dystrophy and congenital glaucoma. *Cornea* 2007; 26:647–649.
12. Khan AO, Al-Shehah A, Ghadhfan FE. High measured intraocular pressure in children with recessive congenital hereditary endothelial dystrophy. *J Pediatr Ophthalmol Strabismus* 2010; 47:29–33.
13. Javadi MA, Baradaran-Rafii AR, Zamani M, *et al*. Penetrating keratoplasty in young children with congenital hereditary endothelial dystrophy. *Cornea* 2003; 22:420–423.
14. Schaumberg DA, Moyes AL, Gomes JA, Dana MR. Corneal transplantation in young children with congenital hereditary endothelial dystrophy. Multicenter Pediatric Keratoplasty Study. *Am J Ophthalmol* 1999; 127:373–378.
15. Goshe JM, Li JY, Terry MA. Successful Descemet's stripping automated endothelial keratoplasty for congenital hereditary endothelial dystrophy in a pediatric patient. *Int Ophthalmol* 2012; 32:61–66. This article illustrates nicely the development of better surgical techniques that can be used in children.
16. Vincent AL, Niederer RL, Richards A, *et al*. Phenotypic characterisation and ZEB1 mutational analysis in posterior polymorphous corneal dystrophy in a New Zealand population. *Mol Vis* 2009; 15:2544–2553.
17. Schmid E, Lisch W, Philipp W, *et al*. A new, X-linked endothelial corneal dystrophy. *Am J Ophthalmol* 2006; 141:478–487.
18. Watts P, Michaeli-Cohen A, Abdolell M, Rootman D. Outcome of lamellar keratoplasty for limbal dermoids in children. *J AAPOS* 2002; 6:209–215.
19. Golubovic S, Latkovic Z, Horvatic-Obradovic M. Surgical treatment of large corneal dermoid. *Doc Ophthalmol* 1995; 91:25–32.
20. Elliott JH, Feman SS, O'Day DM, Garber M. Hereditary sclerocornea. *Arch Ophthalmol* 1985; 103:676–679.
21. Bloch N. Les différents types de sclerocornee, leurs modes d'heredite et les malformations congenitales concomitantes. [The different types of sclerocornee, their modes of inheritance and concomitant congenital malformations]. *J Genet Hum* 1965; 14:133–172.
22. Kelberman D, Islam L, Jacques TS, *et al*. CYP1B1-related anterior segment developmental anomalies novel mutations for infantile glaucoma and von Hippel's ulcer revisited. *Ophthalmology* 2011; 118:1865–1873.
23. Zaidman GW, Flanagan JK, Furey CC. Long-term visual prognosis in children after corneal transplant surgery for Peters anomaly type I. *Am J Ophthalmol* 2007; 144:104–108.
24. Bhandari R, Ferri S, Whittaker B, *et al*. Peters anomaly: review of the literature. *Cornea* 2011; 30:939–944.
25. Weisschuh N, Wolf C, Wissinger B, Gramer E. A novel mutation in the FOXC1 gene in a family with Axenfeld-Rieger syndrome and Peters' anomaly. *Clin Genet* 2008; 74:476–480.
26. Vincent A, Billingsley G, Priston *et al*. Further support of the role of CYP1B1 in patients with Peters anomaly. *Mol Vis* 2006; 12:506–510.
27. Zhang X, Tong Y, Xu W, *et al*. Two novel mutations of the PAX6 gene causing different phenotype in a cohort of Chinese patients. *Eye* 2011; 25:1581–1589.
28. Sanyal S, Hawkins RK. Dysgenetic lens (dyl): a new gene in the mouse. *Invest Ophthalmol Vis Sci* 1979; 18:642–645.
29. Blixt A, Mahlapuu M, Aitola M, *et al*. A forkhead gene, FoxE3, is essential for lens epithelial proliferation and closure of the lens vesicle. *Genes Dev* 2000; 14:245–254.
30. Iseri SU, Osborne RJ, Farrall M, Wyatt AW, *et al*. Seeing clearly: the dominant and recessive nature of FOXE3 in eye developmental anomalies. *Hum Mutat* 2009; 30:1378–1386.
31. Ali M, Buentello-Volante B, McKibbin M, *et al*. Homozygous FOXE3 mutations cause nonsyndromic, bilateral, total sclerocornea, aphakia, microphthalmia and optic disc coloboma. *Mol Vis* 2010; 16:1162–1168.
32. Mondino BJ, Shahinian L Jr, Johnson BL, Brown SI. Peters' anomaly with the fetal transfusion syndrome. *Am J Ophthalmol* 1976; 82:55–58.
33. Martinet V, Dureau P, Bergès O, Caputo G. Vitreoretinal dysplasia masquerading as Peters' anomaly. *Eur J Ophthalmol* 2010; 20:228–230.
34. Sawada M, Sato M, Hikoya A, *et al*. A case of aniridia with unilateral Peters anomaly. *J AAPOS* 2011; 15:104–106.

35. Zinn KM. Changes in corneal ultrastructure resulting from early lens removal in the developing chick embryo. *Invest Ophthalmol* 1970; 9:165–182.
36. Banning CS, Blackmon DM, Song CD, Grossniklaus HE. Corneal perforation with secondary congenital aphakia in Peters anomaly. *Cornea* 2005; 24:118–120.
37. Weisschuh N, Wolf C, Wissinger B, Gramer E. A clinical and molecular genetic study of German patients with primary congenital glaucoma. *Am J Ophthalmol* 2009; 147:744–753.
38. Ali M, McKibbin M, Booth A, *et al.* Null mutations in LTBP2 cause primary congenital glaucoma. *Am J Hum Genet* 2009; 84:664–671.
39. Khan AO, Al-Katan H, Al-Ghedan S, Al-Rashed W. Bilateral congenital stromal cyst of the cornea. *J AAPOS* 2007; 11:400–401.
40. Kelberman D, Islam L, Holder SE, *et al.* Digenic inheritance of mutations in **FOXC1** and **PITX2**: correlating transcription factor function and Axenfeld-Rieger disease severity. *Hum Mutat* 2011; 32:1144–1152.
- The first report of digenic inheritance (*FOXC1* and *PITX2*), implying that if a mutation is found in one of these genes, the other should also be investigated in cases of severe anterior segment developmental anomaly.
41. Wang E, Schnall BM, Rotschild T, *et al.* Unilateral keratitis following death of a twin as the presenting sign of herpetic infection in a neonate. *J AAPOS* 2011; 15:489–490.
42. Gallardo MJ, Johnson DA, Gaviria J, *et al.* Isolated herpes simplex keratoconjunctivitis in a neonate born by cesarean delivery. *J AAPOS* 2005; 9:285–287.
43. Tannen B, Zarbin MA, Bhagat N, *et al.* Corneal autograft and allograft in a 10-month-old premature boy with acquired bilateral corneal opacities. *Cornea* 2011; 30:905–906.
44. Mittal S, Mittal A, Meenakshi R, *et al.* Infectious keratitis in a newborn with goldenhar syndrome. *J Pediatr Ophthalmol Strabismus* 2010; 47:43–45.
45. Kunimoto DY, Sharma S, Reddy MK, *et al.* Microbial keratitis in children. *Ophthalmology* 1998; 105:252–257.
46. Harding SA, Nischal KK, Upponi-Patil A, Fowler DJ. Indications and outcomes of deep anterior lamellar keratoplasty in children. *Ophthalmology* 2010; 117:2191–2195.
47. Ponchel C, Malecaze F, Arné JL, Fournié P. Descemet stripping automated endothelial keratoplasty in a child with descemet membrane breaks after forceps delivery. *Cornea* 2009; 28:338–341.
48. Dangel ME, Bremer DL, Rogers GL. Treatment of corneal opacification in mucopolipidosis IV with conjunctival transplantation. *Am J Ophthalmol* 1985; 99:137–141.
49. Rao KV, Fernandes M, Gangopadhyay N, Vemuganti GK, *et al.* Outcome of penetrating keratoplasty for Peters anomaly. *Cornea* 2008; 27:749–753.
50. Michaeli A, Markovich A, Rootman DS. Corneal transplants for the treatment of congenital corneal opacities. *J Pediatr Ophthalmol Strabismus* 2005; 42:34–44.
51. Yang LL, Lambert SR, Lynn MJ, Stulting RD. Long-term results of corneal graft survival in infants and children with Peters anomaly. *Ophthalmology* 1999; 106:833–848.
52. Dana MR, Schaumberg DA, Moyes AL, Gomes JA. Corneal transplantation in children with Peters anomaly and mesenchymal dysgenesis. Multicenter Pediatric Keratoplasty Study. *Ophthalmology* 1997; 104:1580–1586.
53. Dale N, Sonksen P. Developmental outcome, including setback, in young children with severe visual impairment. *Dev Med Child Neurol* 2002; 44:613–622.
- Not a recent publication but one nevertheless that all pediatric ophthalmologists and those involved in decision making for corneal surgery in infants should read. Visual impairment affects global development in the developing neurobiological system, that is, the infant.
54. Sonksen PM. The assessment of 'vision for development' in severely visually handicapped babies. *Acta Ophthalmol Suppl* 1983; 157:82–90.