REVIEW ARTICLE

Septic Thrombosis of the Cavernous Sinuses

John R. Ebright, MD; Mitchell T. Pace, MD; Asher F. Niazi, MD

Septic thrombosis of the cavernous sinuses (or cavernous sinus thrombophlebitis [CST]) is a dramatic and potentially lethal illness, which is still occasionally seen by clinicians. Before the availability of antimicrobial agents, mortality from CST was near 100%, but it markedly decreased to approximately 20% to 30% during the antibiotic era.[1,2] Nevertheless, the threat of death and serious morbidity continues to necessitate early recognition, diagnosis, and treatment of CST to minimize risks to the patient. Accordingly, we reviewed the salient clinical features of this illness, with emphasis on newer aspects of diagnosis and treatment.

Arch Intern Med. 2001;161:2671-2676

ANATOMY

Two cavernous sinuses are positioned on either side of the sella turcica, which contains the pituitary gland (**Figure 1**). These sinuses are connected by intercavernous sinuses located anterior and posterior to the sella. As is true for all dural venous sinuses, the cavernous sinuses are formed by a separation of the layers of dura mater (specifically, the meningeal and periosteal layers), with trabeculae from each layer crossing the spaces, giving them a reticular or cavernous structure. Immediately below, separated by very thin bone, are the sphenoid sinuses. Of great clinical importance is the intimate relationship of cranial nerves III, IV, V, and VI, which, accompanied by the horizontal segment of the internal carotid artery, run through the lumen in the cases of the artery and abducens nerve or through the outside layers of the cavernous sinuses' lateral walls in the cases of the oculomotor, trochlear, and ophthalmic maxillary branches of the trigeminal nerves.[4,5]

The cavernous sinuses extend from the superior orbital fissure in front backward to the petrous portion of the temporal bone. They receive blood from the superior ophthalmic and cerebral veins and the sphenoparietal sinuses and terminate posteriorly in the superior and inferior petrosal sinuses, which drain into the transverse sinuses and internal jugular veins. In addition, the cavernous sinuses are connected by emissary veins to the pterygoid plexus, which is adjacent to the deep muscles of the face, and also communicates with the deep facial and inferior ophthalmic veins (**Figure 2**).

PATHOGENESIS

The dural sinuses and the cerebral and emissary veins have no valves, which allows blood to flow in either direction according to pressure gradients in the vascular system. This fact and the extensive direct and indirect vascular connections of the centrally located cavernous sinuses make them vulnerable to septic thrombosis resulting from infection at multiple sites. Sinusitis, especially involving the sphenoid and ethmoid sinuses, seems to be the most common primary source of infection predisposing to CST. Infections arising at other locations, such as the face, nose, tonsils, soft palate, teeth (lower and upper), and ears, are less common primary sources since antibiotic therapy has become widely available. Orbital infection is rarely complicated by CST, although the ophthalmic veins drain directly into the orbits.[6]

The most common signs of CST are related to damage of the nerves that traverse the cavernous sinuses (including the parasympathetic and sympathetic nerves accompanying the oculomotor nerve and the internal carotid artery, respectively) and to

From the Departments of Medicine (Drs Ebright and Niazi) and Radiology (Dr Pace), Wayne State University School of Medicine and Detroit Medical Center, Detroit, Mich.

Downloaded from www.archinternmed.com at University of Pittsburgh, on June 2, 2009
©2001 American Medical Association. All rights reserved.

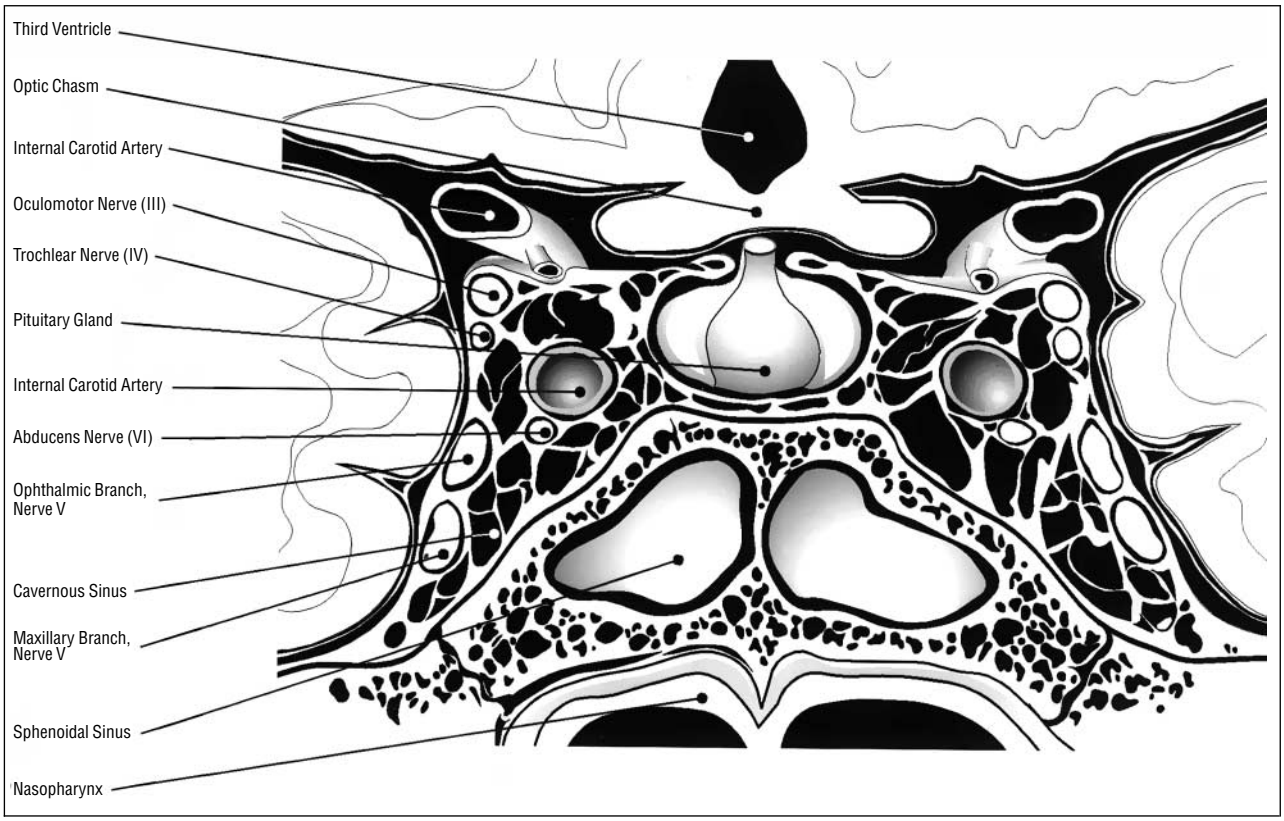

Figure 1. Frontal section through the cavernous sinuses. Copyright 1997. Icon Learning Systems, LLC, a subsidiary of MediMedia USA Inc. Reprinted with permission from ICON Learning Systems, LLC, illustrated by Frank H. Netter, MD. All rights reserved.[3]

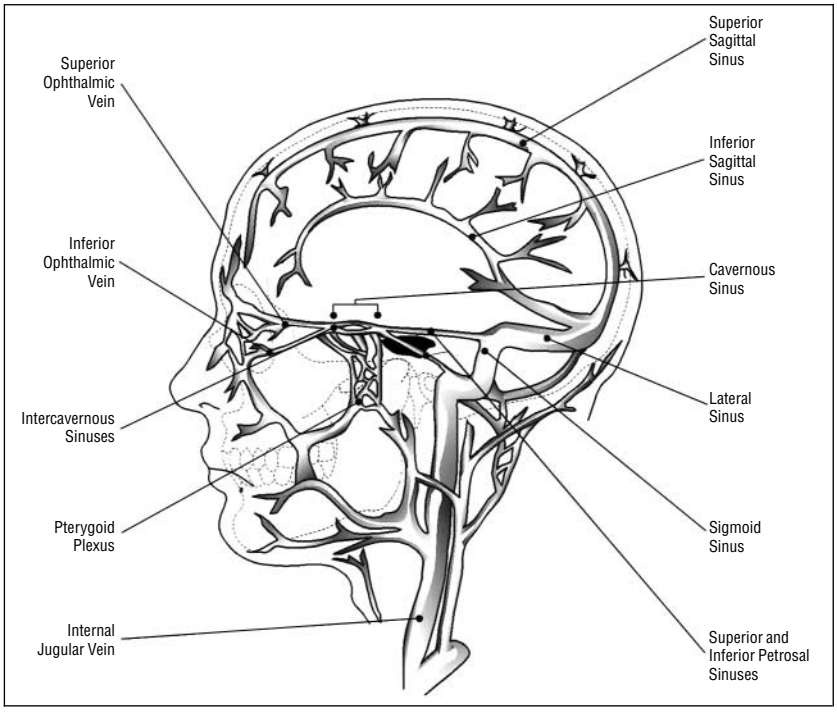

Figure 2. Relationship of the cavernous sinuses to other dural sinuses and veins of the head and face.

engorgement of the retinal and orbital vessels caused by impaired venous drainage. It has been speculated that the trabeculated sinuses act like sieves, trapping bacteria, emboli, and thrombi progressing from anterior infected sites involving the nose, sinuses, or medial third of the face, or in a retrograde fashion from lateral venous sinuses, ears, or teeth. It is possible that more indolent, subacute cases arise from initially sterile thrombi that become infected after extending into the cavernous sinuses and that fulminant, acute cases result from rapid progression of an infected thrombus or septic embolization from a primary infected focus.[7] Irrespective of which mechanism is involved, the presence of enlarging infected clots within a confined cavernous sinus spreading via intercavernous sinuses to involve the opposite side is an ominous complication. Systemic effects from sepsis, local effects from direct injury to cranial nerves III through VI and impaired vascular drainage from the face and eyes, and possible extension into adjacent tissue, causing meningitis, subdural empyema, and pituitary necrosis, together may result in an overwhelming and truly catastrophic illness.

MICROBIOLOGIC FINDINGS

The most commonly identified pathogen in patients with CST con-

Downloaded from www.archinternmed.com at University of Pittsburgh, on June 2, 2009
©2001 American Medical Association. All rights reserved.

Frequency of Symptoms and Physical Abnormalities in Patients With Septic Thrombosis of the Cavernous Sinuses*

Abnormality	Frequency, %
Fever Ptosis Proptosis Chemosis Cranial nerve palsies	80-100
Lethargy Headache Periorbital swelling Papilledema Venous engorgement	50-80
Decreased visual acuity Sluggish or dilated pupil Periorbital sensory loss Decreased corneal reflex Nuchal rigidity	<50
Diplopia Seizures Hemiparesis	<20

*Adapted from Southwick et al,[3] copyright 1986.

tinues to be *Staphylococcus aureus,* identified in 60% to 70% of patients. Less frequently identified are streptococcal species, including *Streptococcus pneumoniae*; gram-negative bacilli; and anerobes.[3] Blood cultures are commonly positive (approximately 70% of cases), especially in patients with acute, fulminant disease, whereas cerebrospinal fluid, abnormal in most patients in terms of elevated white blood cell counts and protein levels, is culture positive in only approximately 20% of cases.[8] Occasionally, fungi such as *Aspergillus* and members of the Mucoraceae family may cause CST.[9-11]

CLINICAL PRESENTATION

Multiple clinical features varying in frequency and severity have been reported, with some, such as septic infarcts of other organs, becoming uncommon since the availability of antibiotic therapy. Another variable in this condition is the timing of the onset of signs and symptoms: patients with acute, fulminant disease will manifest most signs and symptoms rapidly from the outset of illness, and patients with a more subacute course will evidence the features listed in the **Table** sequentially and over several days. Nevertheless, most patients will develop fever, ptosis, proptosis, chemosis, and external ophthalmoplegia during the course of their illness. External ophthalmoplegia, defined as paralysis of the extraocular muscles (in the case of CST, secondary to dysfunction of cranial nerves III, IV, and VI, rather than direct involvement of the extraocular muscles), usually includes all the extraocular muscles. However, it may be more limited or present at least initially with only lateral rectus muscle palsy, especially when disease spreads to the opposite eye. Spread to the opposite eye through the intercavernous sinuses, usually within 24 to 48 hours of the initial unilateral periorbital edema, is a common and characteristic feature of CST. Less frequent, but still seen in most patients, are mild papilledema (usually a late finding), retinal venous engorgement, and altered mental status consisting of lethargy or obtundation. Headaches, an early symptom resulting from either sinusitis or CST, usually are frontal, temporal, or retro-orbital and may be accompanied by tearing. Violaceous edema of the upper lid accompanying periorbital swelling also is common.

Decreased visual acuity, internal ophthalmoplegia, and periorbital sensory alteration secondary to trigeminal nerve (cranial nerve V) dysfunction have been reported in less than half of the patients. Internal ophthalmoplegia, defined as paralysis of the iris and ciliary apparatus, results from dysfunction of parasympathetic nerve fibers carried through the cavernous sinuses and optic canals on the oculomotor (cranial nerve III) nerves or dysfunction of the sympathetic fibers that join them to form the short ciliary nerves. As a result, the pupils may be dilated from parasympathetic paralysis or may be smaller and immobile if both parasympathetic and sympathetic fibers are involved. Sensory alteration within the distribution of the first division of the trigeminal nerve may present as hyperesthesia or hypoesthesia possibly with a depressed corneal response. Diplopia, seizures, and hemiparesis are uncommon.[3,6]

The clinical presentation may be made even more complex as a result of ischemic changes or extension of infection from the cavernous sinuses or primary site of infection to involve the adjacent vascular structures or brain parenchyma. Southwick et al[3] reviewed the pathologic findings of 23 patients who died or underwent surgery during the antibiotic era. Extension of the thrombosis to other venous sinuses, including petrosal, inferior sagittal, sigmoid, and lateral, was observed in 7 patients. Such extension may not only worsen headache, obtundation, and papilledema but may also result in additional findings, such as ear and neck pain, odynophagia, dysphagia, hoarseness, lateral-gaze nystagmus, seizures, and hemiplegia. In addition, the same authors[7] noted 4 cases of pituitary necrosis due to contiguous spread of infection or ischemic damage, 11 cases of meningitis, and 9 cases of brain abscess or subdural empyema, primarily in the fronto-parietal or temporal lobes.[3]

DIFFERENTIAL DIAGNOSIS

Cavernous sinus thrombophlebitis is only 1 (albeit probably the most dramatic) of many causes of painful ophthalmoplegia. The most common condition mimicking acute CST is orbital cellulitis, which commonly causes periorbital swelling, proptosis, chemosis, ophthalmoplegia, fever, decreased vision, and pain.[12] However, bilateral eye involvement, papilledema, decreased periocular sensation, dilated pupils, marked systemic toxic effects, and abnormal spinal fluid are much more likely to be features of CST and aid in differentiating the two conditions. Preseptal cellulitis, which does not cause proptosis and ophthalmoplegia, generally causes little confusion. Orbital apex syndrome, a rare complication of sinusitis, results from inflammation or infection involving 2 clefts in the bony posterior orbit: (1) the superior orbital fissure, which transmits cranial nerves III, IV, and VI and branches of the ophthalmic division of cranial nerve V, and the superior ophthalmic vein, and (2) the optic canal, through which pass the ophthalmic artery and optic nerve. This condition, compared with orbital cellulitis, more typically causes

Downloaded from www.archinternmed.com at University of Pittsburgh, on June 2, 2009
©2001 American Medical Association. All rights reserved.

visual loss and ophthalmoplegia out of proportion to or preceding signs of anterior eye involvement, such as proptosis and periorbital edema. Because the optic nerve passes through the apex but not through the cavernous sinus, impaired vision is more common with the orbital apex syndrome than with CST.[13,14]

Other more indolent or chronic conditions may cause painful ophthalmoplegia owing to involvement of the cavernous sinuses, including local or metastatic malignancy; aseptic thrombosis resulting from trauma, myeloproliferative diseases, or dehydration; granulomatous disease, such as tuberculosis or fungal infection, sarcoid, syphilis, or Tolosa-Hunt syndrome; aneurysm of the internal carotid artery; or carotid-cavernous fistula. Other chronic diseases that may be confused with disease involving the cavernous sinuses are endocrine exophthalmos and ophthalmoplegic migraine.[15-20]

DIAGNOSIS

Before the availability of computed tomography (CT) or magnetic resonance imaging (MRI), CST was diagnosed by its clinical features or at autopsy. Occasionally, cerebral angiography or the more definitive orbital venography was performed, but it was accompanied, at least in the case of orbital venography, by the possibility of serious complications. It was difficult to puncture the frontal veins in patients who were acutely ill with facial edema; in addition, there was much concern that orbital venography, accomplished by injecting contrast material under pressure, may actually disseminate the infection or cause extension of the thrombosis.[21]

The availability of high-resolution enhanced CT scans and, more recently, MRI has remarkably improved our ability to establish the diagnosis of CST using noninvasive technology. Although there is currently some debate regarding which of the two is the procedure of first choice, most experience is with high-resolution CT performed with a slice thickness of 3 mm or less.[22] Abnormal findings include those that are direct signs of CST, consisting of enlargement and expansion of the cavernous sinus with lateral wall flattening or convexity rather than normal concavity, best visualized on coronal images. In addition, multiple irregular or single large filling defects within the enhancing cavernous sinus are highly suggestive direct evidence for thrombi. This is particularly the case when the filling defects are irregular and do not correspond to the anatomic course of neural structures or a thrombosed intracavernous section of the internal carotid artery. They also must be differentiated from intracavernous fat deposits by size (thrombi usually >7 mm), density, and signal intensity.[21-24]

Indirect signs, related to concomitant venous obstruction, consist of dilation of the superior ophthalmic vein, exophthalmos, soft tissue edema, and thrombi visualized in the veins and sinuses tributary to the cavernous sinus (superior ophthalmic vein and superior petrosal, inferior petrosal, and sigmoid sinuses).[21-24]

Magnetic resonance imaging may be of greatest value either to reexamine patients with nondiagnostic CT scans or to further assess complications involving the pituitary gland or extension of infection into adjacent meninges or brain.[21,22] We report a case of probable mucormycosis in which the organism seems to have invaded the cavernous sinuses from the paranasal sinuses to illustrate these points.

REPORT OF A CASE

A 49-year-old woman with a history of diabetes mellitus was admitted to the hospital and treated for diabetic ketoacidosis, which was reversed by the second hospital day. Her course was complicated by severe gastritis and upper gastrointestinal tract bleeding. On the seventh hospital day, she complained of right eye pain and experienced rapid loss of vision, accompanied by right eyelid edema, ptosis, and external and internal ophthalmoplegia. Proptosis was present the following day. Treatment initially was intravenous ampicillin and sulbactam; on the ninth hospital day, high-dose amphotericin B lipid complex was added. By the 11th hospital day, the left eye was also involved, with paralysis of cranial nerves III, IV, and VI; ptosis; and decreased visual acuity. The patient died shortly thereafter secondary to respiratory arrest, presumably from progressive infection of the central nervous system. Permission for autopsy was denied. A biopsy sample from the ethmoid sinus obtained during an open surgical procedure by the ear, nose, and throat service a few days before her death was unrevealing on frozen sections but consistent with mucormycosis on fungal stains of permanent sections.

Computed tomography performed with coronal images of the paranasal sinuses on the eighth hospital day revealed mucous retention cysts in both maxillary sinuses, opacification of the ethmoid sinuses, and mucosal thickening of the left sphenoid sinus. Proptosis was present on the right side. The superior ophthalmic veins did not seem to be engorged. The cavernous sinuses were poorly visualized owing to insufficient intravenous contrast agent within the sinuses. Two days later, an MRI scan revealed mucosal thickening of the sinuses and diminished enhancement in the right cavernous sinus, accompanied by a right cavernous internal carotid artery signal void, which was smaller than that seen on the left (providing presumptive evidence for compression of the right internal carotid artery by thrombus within the sinus). Another MRI the following day revealed the additional finding of a new filling deffect in the left cavernous sinus (**Figure 3**).

MANAGEMENT AND TREATMENT

Management of patients with CST must also include treatment of primary infections, such as sinusitis, dental abscesses, and facial cellulitis, and possible complications, including brain abscesses, meningitis, and extension to other venous sinuses. Initial antibiotic choice, while awaiting culture results, might consist of nafcillin sodium, metronidazole, and ceftriaxone sodium or cefotaxime sodium to treat the patient for the most common organisms associated with this disease.

Downloaded from www.archinternmed.com at University of Pittsburgh, on June 2, 2009
©2001 American Medical Association. All rights reserved.

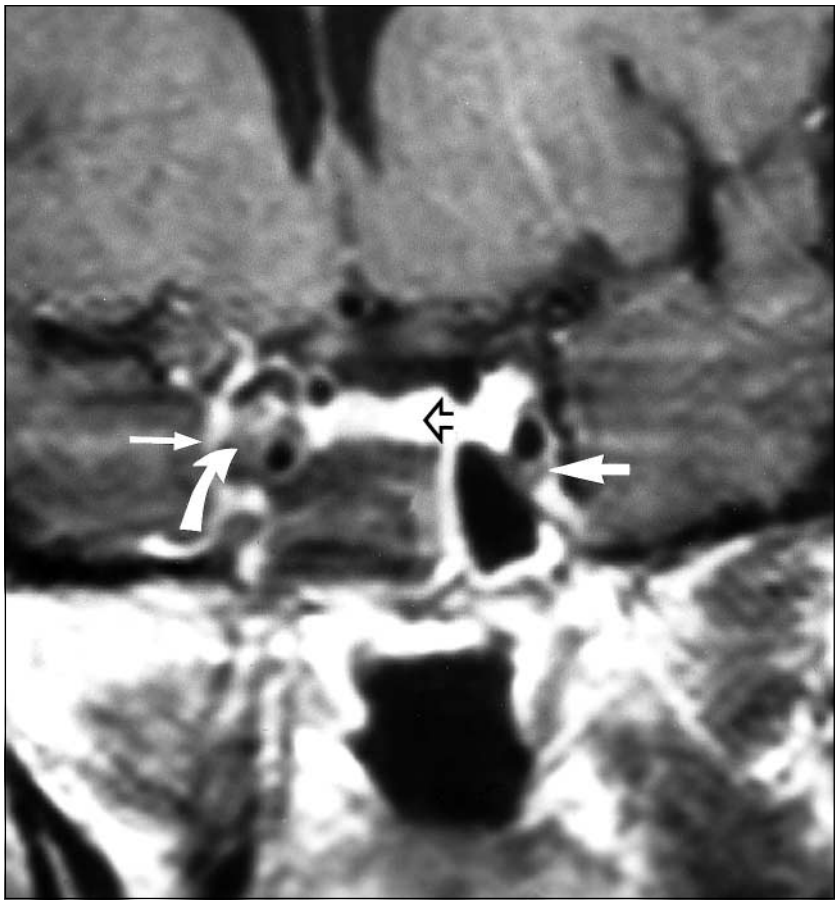

Figure 3. Magnetic resonance image of the cavernous sinuses, with a coronal (frontal), T1-weighted, postgadolinium image through the sella turcica, which reveals a bulging lateral wall of the cavernous sinus (thin arrow) and a large filling defect secondary to thrombus on the right side (curved arrow). The left cavernous sinus demonstrates a small filling defect (large arrow) adjacent to the internal carotid flow void secondary to thrombus from intercavernous spread. The black arrow indicates a portion of the pituitary gland.

Vancomycin could be substituted for nafcillin if the risk of methicillin resistance is high. Doses should be high, appropriate for critically ill patients with intravascular and possible central nervous system infections. The duration of antibiotic therapy is not standardized, but 3 to 4 weeks, consistent with management of other intravascular infections, such as endotheliitis or suppurative phlebitis, seems to be a reasonable projection, especially if signs of inflammation, toxic effects, and fever have ceased during that period.[25]

Surgical drainage of the cavernous sinus is almost never performed, but surgery may be essential for the management of primary sinusitis or dental infection or complicating brain abscess, orbital abscess, or subdural empyema. Similarly, reduction of inflammation and edema by administering systemic corticosteroids is not a well-supported intervention in patients with CST. In a few patients, corticosteroid use may have contributed to improving cranial nerve dysfunction[3,26] or persistent orbital congestion.[27] Rarely, corticosteroid use may play a critical role in caring for patients with adrenal insufficiency secondary to ischemia or necrosis of the pituitary gland.[28,29] Full anticoagulation using heparin, however, is possibly beneficial in select patients. Although no randomized controlled studies have been conducted (and because of the infrequency of this disease, probably never will be conducted), recent retrospective reviews provide some support for heparin use in the absence of cortical venous infarction. Anticoagulant therapy begun early (ie, within 7 days of hospitalization for CST) may reduce morbidity rates in survivors.[30] In particular, a reduction in diplopia from cranial nerve dysfunction, unilateral blindness, seizures, hemiparesis, and hypopituitarism may be observed. The review by Southwick et al[3] suggests that early anticoagulant therapy in patients with unilateral CST may also reduce mortality rates. Duration of anticoagulant therapy with warfarin sodium after initial heparin therapy is unknown, but 4 to 6 weeks has been suggested.[30]

MORBIDITY AND MORTALITY

Mortality has decreased from 80% to 100% in the preantibiotic era to 20% to 30% since 1940. In addition, Yarington[2] points to a decrease in morbidity from 50% to 75% to only 22%. Nevertheless, the threat of temporary complications and long-term sequelae remains. In a review published early in the antibiotic era, Shaw[7] described 60 patients treated with either sulfonamides or penicillin: 53 recovered, but most (77%) had complications or long-term sequelae. Twenty-five patients had metastatic infection primarily involving the lungs, with abscesses, empyema, and pneumonia. Nine patients developed orbital abscesses and 5 developed abscesses in the brain. Prolonged cranial nerve dysfunction, especially of nerves III and VI, were the most common long-term sequelae; 5 patients developed unilateral blindness, and 4 had decreased visual acuity. Prominent facial veins and spastic paresis of the arm were also noted but were unusual.[7] A more recent review[3] of 96 patients treated since 1940 found 29 to have long-term sequelae, including oculomotor (cranial nerve III) weakness in 16 (17%) of 95 patients, blindness in 16 (17%), pituitary insufficiency in 2 (2%), and hemiparesis in 3 (3%). The cause of blindness has been speculated to be pressure on the retinal artery and vein at the orbital apex, arteritis of the internal carotid artery, emboli to the retinal artery, or toxic neuropathy of the optic nerve.[31] Pituitary insufficiency, a rare but well-documented event, results from either infarction or extension of infection into the sella turcica.[29] Hemiparesis may be a consequence of internal carotid artery occlusion, cerebral abscess, or cortical vein thrombosis.[30]

Downloaded from www.archinternmed.com at University of Pittsburgh, on June 2, 2009
©2001 American Medical Association. All rights reserved.

CONCLUSIONS

Although rare, CST remains a dramatic and potentially lethal complication of infections involving the sinuses, face, ears, and oral cavity. Early recognition and differentiation from other diseases that can mimic it coupled with aggressive medical and possible surgical intervention are key to reducing mortality rates and long-term sequelae. Recent improvements in imaging, especially CT and MRI, have contributed substantially to the rapid diagnosis of this condition.

Accepted for publication April 9, 2001.

Corresponding author and reprints: John R. Ebright, MD, Division of Infectious Diseases, Harper Hospital, 3990 John R, 4 Brush Center, Detroit, MI 48201 (e-mail: jebright@intmed.wayne.edu).

REFERENCES

1. Clune JP. Septic thrombosis within the cavernous chamber. *Am J Ophthalmol.* 1963;56:33-39.
2. Yarington CT. Cavernous sinus thrombosis revisited. *Proc R Soc Med.* 1977;70:456-459.
3. Southwick FS, Richardson EP, Swartz MN. Septic thrombosis of the venous dural sinuses. *Medicine (Baltimore).* 1986;65:82-106.
4. Woodburne RT, Burkel WE. The head and neck. In: *Essentials of Human Anatomy.* 9th ed. New York, NY: Oxford University Press; 1994:325-326.
5. VanOverbeake JJ, Jansen JJ, Tulleken CAF. The cavernous sinus syndrome: an anatomical and clinical study. *Clin Neurol Neurosurg.* 1988;90:311-319.
6. DiNubile MJ. Septic thrombosis of the cavernous sinuses. *Arch Neurol.* 1988;45:567-572.
7. Shaw RE. Cavernous sinus thrombophlebitis: a review. *Br J Surg.* 1952;40:40-48.
8. Taylor PJ. Cavernous sinus thrombophlebitis. *Br J Ophthalmol.* 1957;41:228-237.
9. Sekhar LN. Carotid-cavernous sinus thrombosis caused by *Aspergillus fumigatus. J Neurosurg.* 1980;67:219-222.
10. Estrem SA, Tully R, Davis WE. Rhinocerebral mucormycosis: computed tomographic imaging of cavernous sinus thrombosis. *Ann Otol Rhinol Laryngol.* 1990;99:160-161.
11. Dooley DP, Hollsten DA, Grimes SR, Moss J. Indolent orbital apex syndrome caused by occult mucormycosis. *J Clin Neuroophthalmol.* 1992;12:245-249.
12. Price CD, Hameroff SB, Richards RD. Cavernous sinus thrombosis and orbital cellulitis. *South Med J.* 1971;64:1243-1247.
13. Colson AE, Daily JP. Orbital apex syndrome and cavernous sinus thrombosis due to infection with *Staphylococcus aureus* and *Pseudomonas aeruginosa. Clin Infect Dis.* 1999;29:701-702.
14. Kronschnabel EF. Orbital apex syndrome due to sinus infection. *Laryngoscope.* 1974;84:353-371.
15. Hunt WE, Meagher JN, LeFever HE, Zeman W. Painful ophthalmoplegia: its relation to indolent inflammation of the cavernous sinus. *Neurology.* 1961;11:56-62.
16. Jellinek EH. The orbital pseudotumour syndrome and its differentiation from endocrine exophthalmos. *Brain.* 1969;92:35-58.
17. Ryan MW, Rassekh CH, Chaljub G. Metastatic breast carcinoma presenting as cavernous sinus syndrome. *Ann Otol Rhinol Laryngol.* 1996;105:666-668.
18. Lovel T, Marsan RE. Carotid cavernous fistula. *Angiology.* 1974;25:231-236.
19. Grayeli AB, Redondo A, Salama J, Rey A. Tuberculoma of the cavernous sinus: case report. *Neurosurgery.* 1998;42:179-181.
20. Brismar G, Brismar J. Aseptic thrombosis of orbital veins and cavernous sinus. *Acta Ophthalmologica.* 1977;55:9-22.
21. Berge J, Louail C, Caille JM. Cavernous sinus thrombosis diagnostic approach. *J Neuroradiol.* 1994;21:101-117.
22. Schuknecht B, Simmen D, Yuksel C, Valavanis A. Tributary venosinus occlusion and septic cavernous sinus thrombosis: CT and MRI findings. *AJNR Am J Neuroradiol.* 1998;19:617-626.
23. Ben-Uri R, Palma L, Kaveh Z. Case report: septic thrombosis of the cavernous sinus: diagnosis with the aid of computed tomography. *Clin Radiol.* 1989;40:520-522.
24. Ahmadi J, Keane JR, Segall HD, Zee CS. CT observations pertinent to septic cavernous sinus thrombosis. *AJNR Am J Neuroradiol.* 1985;6:755-758.
25. Zahllar M, Spector RH, Skoglund RR, Digby D, Nyhan WL. Cavernous sinus thrombosis. *West J Med.* 1980;133:44-48.
26. Solomon OD, Moses L, Volk M. Steroid therapy in cavernous sinus thrombosis. *Am J Ophthalmol.* 1962;54:1122-1124.
27. Friberg TR, Sogg RL. Ischemic optic neuropathy in cavernous sinus thrombosis. *Arch Ophthalmol.* 1978;96:453-456.
28. Karlin FJ, Robinson WA. Septic cavernous sinus thrombosis. *Ann Emerg Med.* 1984;13:449-455.
29. Ivey KJ, Smith H. Hypopituitarism associated with cavernous sinus thrombosis. *J Neurol Neurosurg Psychiatry.* 1968;31:187-189.
30. Levine SR, Twyman RE, Gilman S. The role of anticoagulation in cavernous sinus thrombosis. *Neurology.* 1988;38:517-522.
31. Geggel HS, Insenberg SJ. Cavernous sinus thrombosis as a cause of unilateral blindness. *Ann Ophthalmol.* 1982;14:569-574.

Downloaded from www.archinternmed.com at University of Pittsburgh, on June 2, 2009
©2001 American Medical Association. All rights reserved.