

Use of this content is subject to the Terms and Conditions

Supranuclear control of ocular motility

[Ophthalmology Clinics of North America](#) - [Volume 14, Issue 1](#) (March 2001) - Copyright © 2001 W. B. Saunders Company

Neuro-Ophthalmology

Supranuclear control of ocular motility

Lea Averbuch-Heller MD

From the Neuro-Ophthalmology Service, Departments of Neurology and Ophthalmology, Rabin Medical Center, Tel Aviv University, Petach-Tikva, Israel

This article was partially supported by German-Israeli Fund grant I-574.

Address reprint requests to, Lea Averbuch-Heller, MD, 2-B HaGai Street, Beit Hakerem, Jerusalem 96262, Israel, e-mail: lah@netvision.net.il

Copyright © 2001 by Mosby, Inc.

0896-1549/01 \$15.00 + .00

Under natural circumstances, gaze shifts are accomplished by a complex combination of many individual eye movements. Such arrangement requires exquisite coordination between numerous structures involved in ocular motor control. A plethora of new evidence emanating from animal studies expanded and modified traditional schemes of premotor organization of the ocular motor system. In this article, the functional mechanisms concerned with programming eye movements are outlined, current knowledge of the relevant neuroanatomy is presented, and clinical disorders of supranuclear control of ocular motility are discussed. For further details on these topics, the reader is referred to standard texts. [\[47\]](#) [\[53\]](#)

Functional Classes of Eye Movements and Binocular Control

Eye movements are subservient to vision. Their goal is to bring an object of interest onto the fovea and keep it there steadily. Whereas the ultimate command for an eye movement comes from the nuclei of III, IV, and VI cranial nerves, diverse premotor signals converge on the nuclei. These signals derive from several distinct functional classes of eye movements all aimed at optimizing vision during various activities (Table 1).

Table 1. Functional classes of eye movements

Class	Primary Function
Fixation	Holds the image of a stationary object on the fovea
Vestibulo-ocular reflex	Holds images steady on the retina during brief head rotations
Optokinetic	Holds images steady on the retina during sustained head rotations
Smooth pursuit	Holds the image of a small moving target close to the fovea
Neural integrator	Holds the eyes steady in an eccentric orbital position

Saccades	against elastic forces of orbital tissues Place images of eccentrically located objects on the fovea by moving both eyes in the same direction
Vergence	Places images of a single object on both foveas during gaze shifts in depth by moving the eyes in opposite directions

In general, eye movements can be divided into two groups of mechanisms: gaze-holding and gaze-shifting.

Eye Movement Mechanisms

Gaze-holding mechanisms act to prevent slip of images on the retina. Steady gaze-holding is achieved by collaboration of vestibular and visually mediated mechanisms. Vestibulo-ocular reflexes operate during locomotion, generating compensatory eye movements to counteract high-frequency head perturbations that occur with each step. One remarkable property of vestibulo-ocular reflexes is their short latency (less than 15 ms). The loss of these reflexes (e.g., caused by gentamycin toxicity) invariably results in blurred vision or oscillopsia during locomotion, as long delays of the visual system (about 100 ms) make it unsuitable for rapid compensation. If head rotations are slow and sustained, visual system can stabilize gaze by producing optokinetic eye movements. Similarly, during linear self-motion or while tracking a small moving target, visually driven smooth pursuit contributes to holding the image steadily on the fovea. The fixation mechanism monitors excessive slip of images on the retina, programs corrective responses, and suppresses unwanted saccades. Neural integration deals with sustaining steady gaze in eccentric orbital positions. To overcome mechanical forces of the suspensory ligaments and fascia that tend to pull the globe back to midposition, the brain has to devise an appropriate command by transforming velocity to position signal. When this "integrator" function is impaired, gaze-evoked nystagmus occurs.

Gaze-shifting mechanisms act to redirect the line of sight to a new object of interest in the visual periphery. Saccades are rapid, conjugate movements that bring the image onto fovea. Saccades can be generated voluntarily or in response to external (visual, auditory, somatosensory, or vestibular) stimuli. Vergence is at work during gaze shifts in depth between far and near targets. Unlike all the aforementioned version movements, vergence is an essentially disconjugate system. It moves the eyes in opposite directions (i.e., disjunctive eye movements), so the images of a single object fall on foveas of both eyes simultaneously.

Various classes of eye movements do not function in isolation but work in concert to provide exact foveal placement of the object of interest.^[43] In spite of the traditional separation between conjugate version and disconjugate vergence systems, the differentiation between these two classes of eye movements is artificial. Horizontal saccades are inherently disconjugate, as abducting saccades are faster than adducting ones. In everyday life, pure version rarely is exercised. The majority of horizontal gaze shifts are accompanied by changes in depth, calling for cooperation of version and vergence mechanisms.^[68] ^[86]

Binocular Coordination

To grant stereopsis (i.e., depth perception) and avoid diplopia, movements of both eyes have to be coordinated precisely. The neural basis of binocular coordination still is elucidated incompletely. According to the prevailing Hering's law, the brain treats the two eyes as one single eye: common innervation signals drive both eyes together, providing coordination of eye movements. This yoking is believed to be embedded in the anatomic arrangement of the excitatory burst neurons and the way these neurons project onto motoneurons of the ocular motor nuclei of both eyes.^[54] Evidence challenging this deep-rooted concept of binocular control seems to partly support an opposing opinion voiced by Helmholtz in the late ninth century. According to Helmholtz, each eye is governed independently, and the observed binocularly coordinated behavior is learned.^[88] ^[89] In support of this view, Zhou and King showed that during sleep, eye movement in monkeys are disconjugate or even monocular.^[88] In a neurophysiologic study that further vindicates the monocular control theory, premotor neurons in the paramedian pontine reticular formation were found to encode monocular commands for right or left eye saccades.^[89] Analysis of prism-induced adaptation in normal human subjects demonstrated that binocular mechanisms (i.e., saccade-vergence interaction) and monocular mechanisms participate in the disconjugate adaptation.^[5] Relative contribution of monocular versus binocular

control is yet to be established.

Neuroanatomy of Supranuclear Ocular Motor Control

The entire brain is involved in planning and executing ocular motor behavior. Centrally programmed saccadic, pursuit, vestibular, optokinetic, and vergence commands descend in parallel pathways eventually to reach ocular motoneurons. Some of this circuitry is still unclear; however, functional scanning in humans, such as PET and functional MR (fMR) imaging, complemented neurophysiologic data from animal research and allowed the drawing of explicit schemes of supranuclear ocular motor control. This article approaches the presumed profile of the system by starting with the cortical areas and descending pathways, proceeding with cerebellar modulation, and concluding with the brainstem apparatus responsible for carrying out all eye movement commands.

Cortical Control

Several cortical areas are engaged in ocular motor control. Although these areas traditionally are viewed as an assortment of “centers” in which each is concerned with a separate function, it seems that parallel distributed processing of various inputs is required to accomplish real-life gaze shifts. Assigning each area to one specific function proved incorrect. Frontal eye fields, though best studied for saccades, also participate in fixation, pursuit, and vergence control; the same probably is true of other cortical areas. As a rule, reflexive, stimulus-bound eye movements of various types originate in posterior parts of the brain, whereas voluntary, self-initiated movements derive from frontal areas.

Frontal cortex includes three areas involved in saccade generation. These comprise the frontal eye fields (FEFs), supplementary eye fields (SEFs), and dorsolateral prefrontal cortex (DLPC). Some neurons of the FEFs discharge for visually guided and memory-guided saccades, fixation, or vergence movements. [25] [26] [28] [66] SEFs contribute to control of learned patterns of complex ocular motor behaviors, whereas DLPC deals with planning saccades to remembered targets. Parietal cortex is important to shifting visual attention. It also contributes to saccade initiation. Parietal eye fields project to the FEFs and participate in exploring visual scene and triggering reflexive visually guided saccades. Acute damage to parietal and frontal eye fields results in inability to direct the eyes contralaterally and produces transient ipsilesional gaze deviation. Primary visual (striate) cortex is crucial for generating smooth pursuit and optokinetic eye movements and for optimizing saccadic accuracy. [72] The temporo-parieto-occipital junction is concerned with motion perception and the tracking of moving targets (smooth pursuit). This area is responsible for cortical motion processing and is capable of programming reflexive three-dimensional eye movements with short latencies before the person is aware of a visual disturbance. [52]

Descending Pathways

Several pathways project in parallel to subcortical and brainstem structures involved in ocular motor control. Projections of areas concerned with saccades are contralateral, whereas those saccades concerned with pursuit are mainly ipsilateral. For purely vertical gaze shifts, corresponding areas of both hemispheres undergo concurrent activation. The descending ocular motor connections differ from those of the skeletal motor system in that they do not perpetrate the usual “upper motor neuron–lower motor neuron” sequence. Cortical neurons do not project directly to ocular motoneurons in the brainstem. For both saccades and pursuit, the descending pathways are polysynaptic with numerous intermediate stations on the way to their final destination.

The normal mechanism by which saccades are controlled relies on parallel inhibitory and excitatory pathways descending from the frontal eye fields directly, by way of the basal ganglia onto the superior colliculus, and from there (and also directly) to the brainstem reticular formation (Fig. 1).

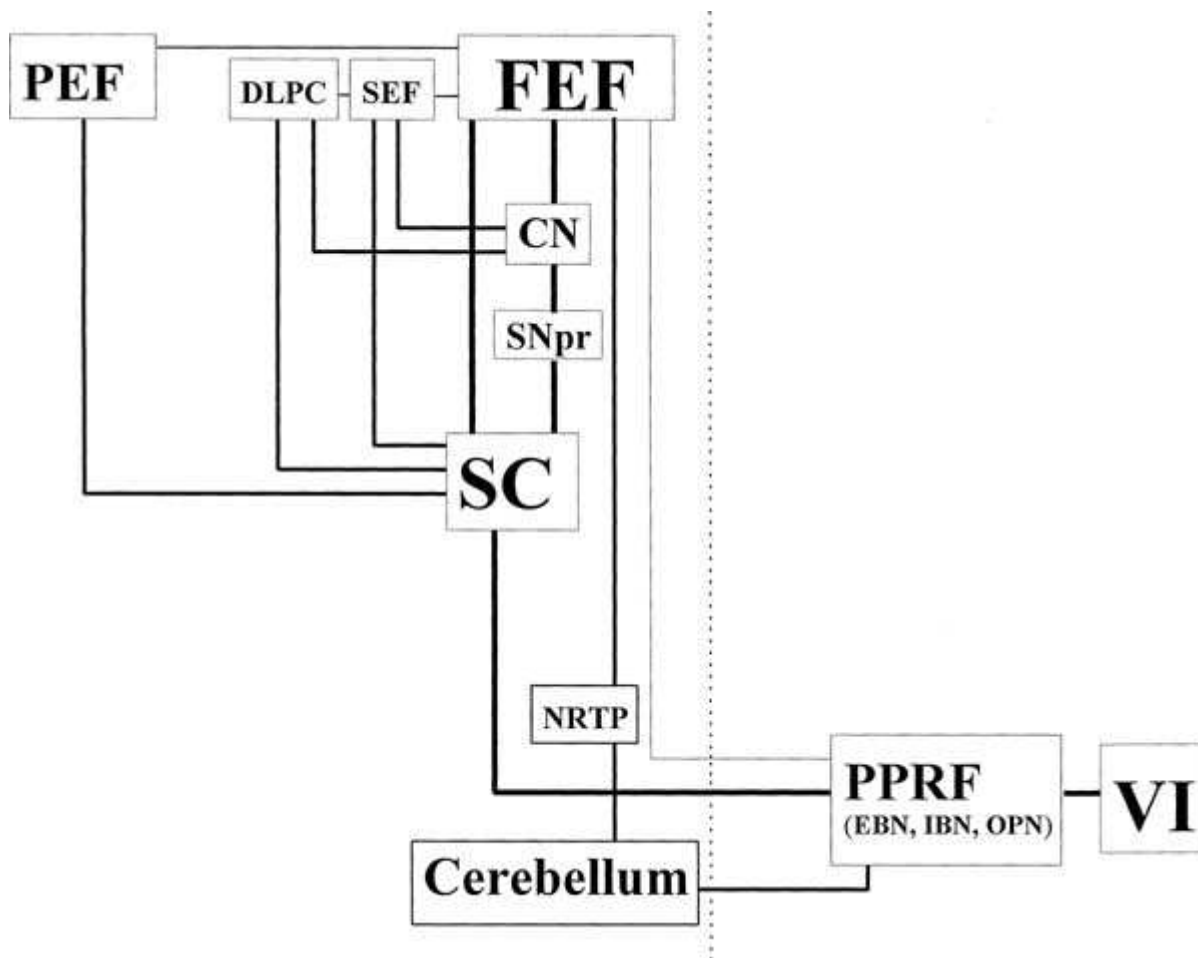


Fig. 1. Descending parallel pathways involved in control of horizontal saccades and fixation. FEF = frontal eye fields; DLPC = dorsolateral prefrontal cortex; SEF = supplementary eye fields; PEF = parietal eye fields; CN = caudate nucleus; SN_{pr} = substantia nigra pars reticulata; SC = superior colliculus; N RTP = nucleus reticularis tegmenti pontis; PPRF = pontine paramedian reticular formation; EBN = excitatory burst neurons; IBN = inhibitory burst neurons; OPN = omnipause neurons; VI = the abducens nucleus; dotted line = midline.

The indirect, striatonigral-collicular pathway can be viewed as a chain of two inhibitory links: (1) caudo-nigral projections that phasically inhibit the (nondopaminergic) substantia nigra pars reticulata and (2) nigro-collicular projections that maintain tonic inhibition of saccades. When a saccade is made, activation of the frontal cortex causes excitation of neurons in the caudate nucleus, which in turn suppresses the nigro-collicular inhibition so that the superior colliculus can release saccadic command. An additional descending projection from the FEF obviates the basal ganglia and the superior colliculus, traveling directly to the nucleus reticularis tegmenti pontis (N RTP) and from there to the cerebellum.

The superior colliculus represents the main station on the way to saccade generation. It interacts bidirectionally with the FEF^[75] and consists of several functionally and anatomically distinct zones. Its rostral pole is important for fixation, and the more caudal region contains neurons responsible for activation of saccades. These “saccade-related” cells in the superior colliculus are under tonic inhibition of the substantia nigra, while the fixation cells receive direct input from the “fixation” cells in the frontal eye fields.^{[57] [58]} Although lesions confined to the superior colliculus have only minor and transient effects on eye movements,^[65] combined damage to the frontal cortex and superior colliculus or to both frontal and parietal eye fields affects all the descending projections, and produces severe and longstanding ocular motor dysfunction.

Pathways important for smooth pursuit descend from temporo-parieto-occipital junction and FEF to the ipsilateral dorsolateral pontine nuclei (Fig. 2).

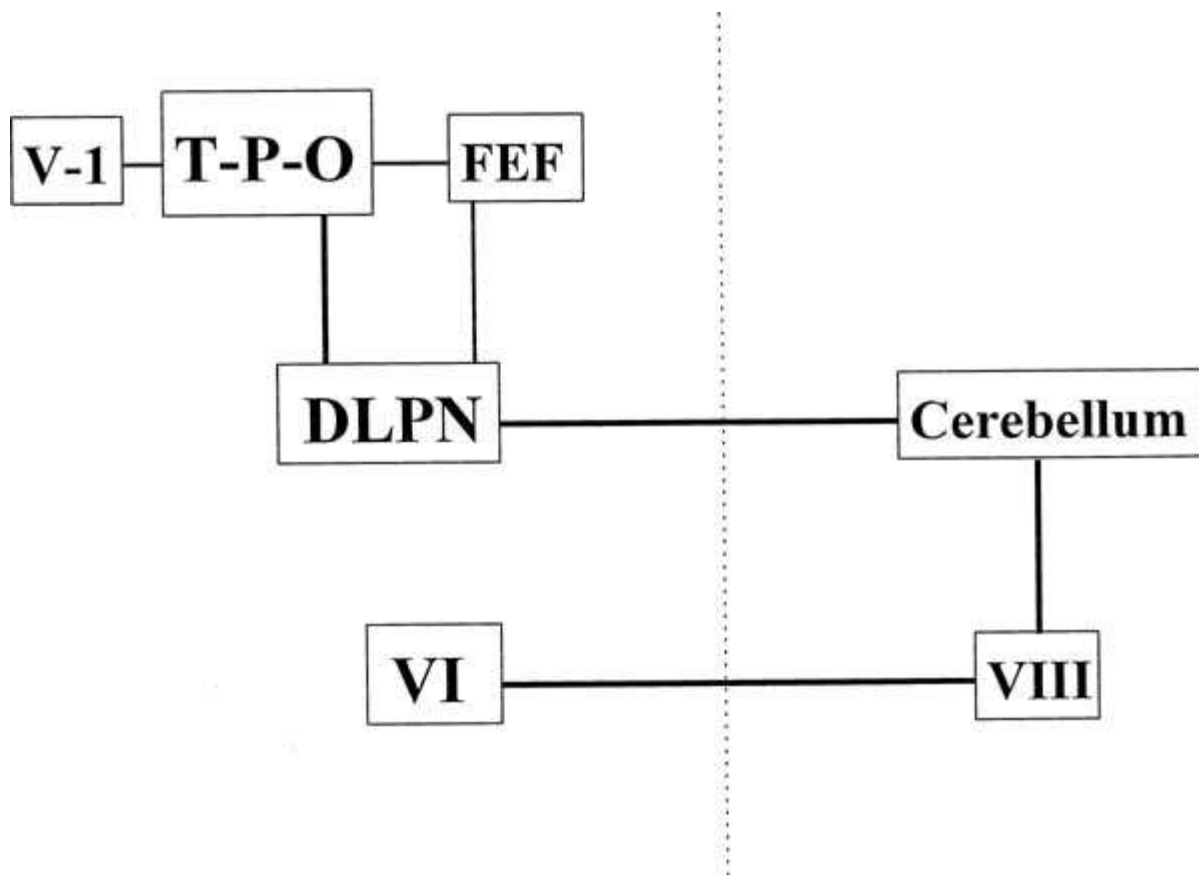


Fig. 2. Descending projections involved in control of horizontal pursuit. V-1 = primary visual cortex; T-P-O = temporo-parieto-occipital junction; FEF = frontal eye fields; DLPN = dorsolateral pontine nuclei; VIII = vestibular nuclei; VI = the abducens nucleus; dotted line = mid line. Note that in spite of the double decussation, the pursuit pathway is essentially ipsilateral.

From there, axons decussate to reach cerebellar flocculus. The flocculus projects to the ipsilateral vestibular nuclei whose projections cross again to finally end up on the abducens nucleus—on the side of the cortical neurons where the chain has originated—thus rendering the whole pursuit pathway essentially ipsilateral.

Cerebellar Contribution

Cerebellum plays an important role in fine tuning all eye movements, including modulation and adaptation of vestibulo-ocular responses, saccades, pursuit, and vergence. Two distinct parts of the cerebellum contribute to ocular motor control: (1) the vestibulocerebellum (flocculus, paraflocculus, nodulus, and ventral uvula) and (2) the dorsal vermis of the posterior lobe and fastigial nuclei. The vestibulocerebellum deals with stabilization of sight during motion, whereas the dorsal vermis and fastigial nuclei influence voluntary gaze-shifting (i.e., saccades, pursuit and vergence).

Cerebellar Modulation of the Vestibulo-ocular Reflex

The flocculus is crucial in the adaptive control of the vestibulo-ocular reflex. [48] It receives inputs from structures important for neural integration and sends efferents to the vestibular nuclei. The nodulus and uvula are responsible for the velocity-storage mechanism through which secondary vestibular neurons prolong their responses beyond those of the primary vestibular neurons. [18] Velocity storage is implicated in the pathogenesis of periodic alternating nystagmus (PAN).

Cerebellar Modulation of Saccades and Pursuit

Dorsal vermis takes part in controlling contralateral saccades and pursuit. [30] [31] [60] It receives afferents from the ipsilateral structures responsible for saccades, pursuit, and vestibulo-ocular reflexes, and in turn sends efferents to the fastigial nucleus. Neurons in the fastigial nucleus contribute to accelerating contralateral saccades and pursuit. The fastigial nucleus projects through the uncinate fasciculus to the

contralateral brainstem generators of horizontal and vertical saccades. Lesions of medulla affecting inputs to the fastigial nucleus therefore produce hypermetric ipsilateral saccades (i.e., "lateropulsion"), whereas midbrain lesions affecting its outputs result in hypermetric contralateral saccades.

Cerebellar Modulation of Vergence

Neurons in the fastigial nucleus and nucleus interpositus project to the midbrain near-response cells. A study using single-unit recording demonstrated a far-response region within a posterior nucleus interpositus. Neurons located in this region are active during divergence and accommodation for a far stimulus in which the response is elicited by blur and disparity cues. [87]

Brainstem Circuitry

On the brainstem level, premotor control of horizontal and vertical gaze is divided anatomically. Structures involved in horizontal gaze generation occupy the lower pons and upper medulla, whereas those structures important for vertical gaze reside in the rostral midbrain. Vergence control is distributed between the midbrain and pons.

Horizontal Gaze

The ultimate structure concerned with conjugate horizontal gaze is the abducens nucleus. Neural commands for all functional classes of eye movement reach the abducens nucleus (Fig. 3).

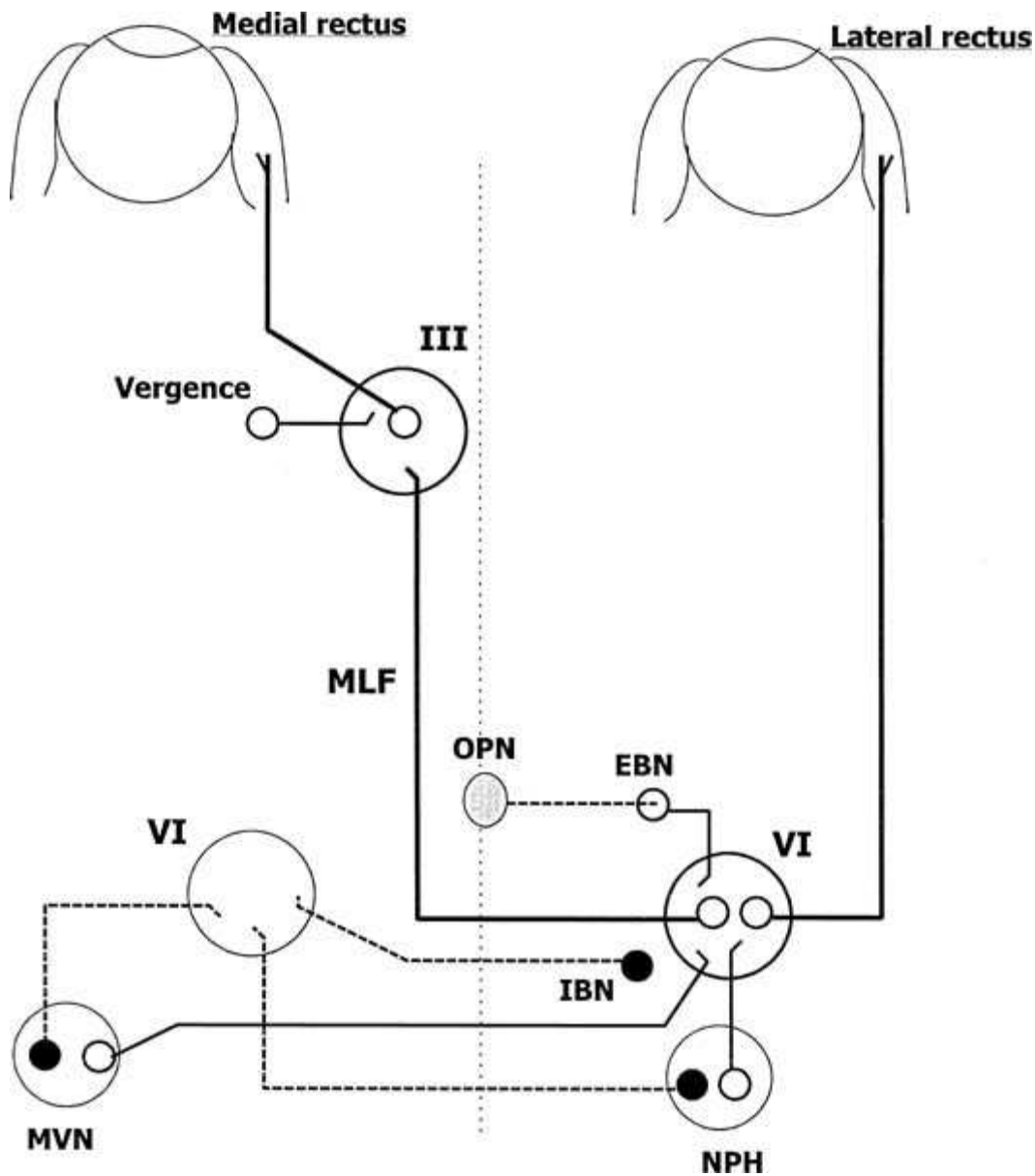


Fig. 3. Brainstem control of horizontal eye movements. The abducens nucleus (VI) is a “center” for horizontal gaze. It houses two populations of neurons: abducens motoneurons that project to the lateral rectus and internuclear neurons that decussate and project to the medial rectus subnucleus of the oculomotor nucleus (III) by way of the contralateral medial longitudinal fasciculus (MLF). Saccadic, pursuit, and integrator commands all join on VI (for details see text); vergence signal accesses III directly. Black symbols and dashed lines represent inhibitory inputs; open symbols and solid lines represent excitatory inputs. NPH = nucleus prepositus hypoglossi; MVN = medial vestibular nucleus; EBN = excitatory burst neurons; IBN = inhibitory burst neurons; OPN = omnipause neurons; dotted line = midline.

Unlike other motor nucleus, it governs the ipsilateral muscle to which it projects (lateral rectus) AND the contralateral agonist, yoke muscle (medial rectus). The abducens nucleus functions as the horizontal gaze center. It contains two neuronal populations: (1) abducens motoneurons whose axons run in the ipsilateral sixth nerve and (2) internuclear neurons whose axons cross to join the contralateral medial longitudinal fasciculus (MLF) and ascend to the contralateral medial rectus subnucleus.^{[41] [59]} In the opposite direction, oculomotor internuclear neurons, which lie in the medial rectus subnucleus of the oculomotor nuclear complex, descend to the contralateral abducens nucleus.^[17] Jointly, the two groups of internuclear neurons provide the anatomic basis for coupling of horizontal movements in both eyes (i.e., Hering's law). Lesions to the abducens nucleus result in inability to drive both eyes ipsilesionally in any kind of eye movements. Damage to the MLF produces clinical picture of internuclear ophthalmoplegia with impaired adduction on the side of the lesion.

Saccade signals reach the abducens nucleus from neurons in the paramedian pontine reticular formation

(PPRF). [39] [78] [79] PPRF houses three kinds of neurons necessary for horizontal saccades (see Fig. 3). (1) Excitatory burst neurons located just rostrally to the abducens nucleus receive their input mainly from the contralateral superior colliculus. They project directly to the ipsilateral abducens nucleus and stimulate it for an ipsilateral saccade. Damage to these neurons causes an inability to generate ipsilateral saccades. (2) Inhibitory burst neurons located at the pontomedullary junction project to the contralateral abducens nucleus and are meant to inhibit the antagonist, contralateral lateral rectus during ipsilateral abduction. (3) Omnipause neurons (OPNs) located in a distinct paramedian, glycinergic, nucleus raphe interpositus subserve suppression of saccades during visual fixation. OPNs receive input from the rostral fixation zone of the superior colliculus and project to horizontal and vertical excitatory burst neurons. [14] OPN activity has to be suppressed for saccades to be made. Lesions of OPN may result in saccadic intrusions up to opsoclonus or slow saccades.

The signals for eccentric gaze-holding reach the abducens nucleus from the nucleus prepositus hypoglossi (NPH) and *the* medial vestibular nuclei (MVN)—structures that function as neural integrators for horizontal gaze. [80] The NPH, MVN, and their cerebellar connections are crucial for providing an eye position signal for a tonic contraction of the extraocular muscles used to hold the eye steady in an eccentric position against the elastic forces of the orbital tissues. Lesions involving NPH and MVN cause poor horizontal gaze-holding and gaze-evoked nystagmus. Excitatory vestibular and optokinetic inputs originate in the contralateral vestibular nuclei. [44] A smooth pursuit pathway projects to the abducens nucleus from the ipsilateral dorsolateral pontine nuclei through the contralateral vestibular and cerebellar nuclei.

Vertical Gaze

The premotor excitatory burst neurons for vertical eye movement lie in the rostral interstitial nucleus of the MLF (riMLF) at the meso-diencephalic junction (Fig. 4).

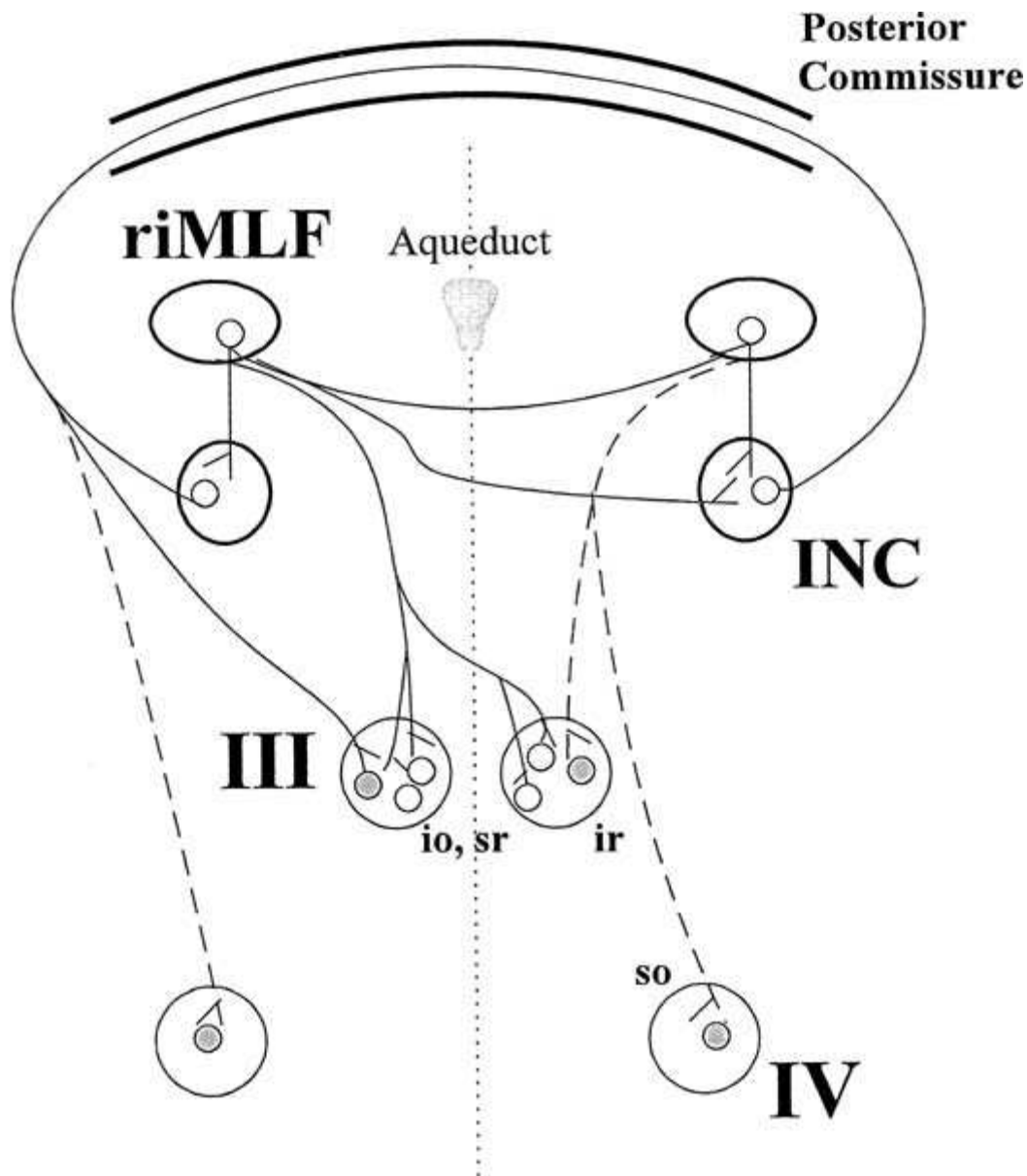


Fig. 4. Brainstem control of vertical gaze. The rostral interstitial nucleus of the LF (riMLF) on each side contains excitatory burst neurons for upward and downward saccades and ipsitorsional saccades. Projections from riMLF onto motoneurons of the depressor muscles subnuclei—inferior rectus (ir) and superior oblique (so)—are mainly ipsilateral, whereas projections onto the elevator muscles subnuclei are bilateral. Note that the interstitial nucleus of Cajal (INC) decussates extensively in the posterior commissure, whereas riMLF decussates ventrally to the aqueduct. For details, see text. III = the oculomotor nucleus; IV = the trochlear nucleus; sr = superior rectus; io = inferior oblique; dotted line = midline.

The riMLF contains burst neurons for vertical and torsional saccades. Neurons of each riMLF fire for upward and downward eye movements and only for ipsilateral torsional saccades. [55] [56] [84] The riMLF projects to motoneurons of elevator muscles bilaterally but projects to motoneurons of depressor muscles only ipsilaterally. Each burst neuron in the riMLF sends collaterals to motoneurons supplying yoke muscle pairs in the two eyes (e.g., superior rectus to inferior oblique, inferior rectus to superior oblique). This arrangement underlies preservation of Hering's law in the vertical plane. [54] Unilateral riMLF lesions cause the slowing of downward saccades and torsional nystagmus with a contralesionally beating quick phase. Bilateral lesions abolish all vertical saccades. [81]

In the vertical plane, neural integrator function (eccentric gaze-holding) is performed by an interstitial nucleus of Cajal (INC). [22] [42] The INC projects by way of the posterior commissure to motoneurons of the contralateral nuclei of the third and fourth cranial nerves and the contralateral INC (see Fig. 4). [16] The INC

also receives inputs necessary for vertical vestibular and smooth pursuit eye movements that arise from the medulla and pons; some of those inputs travel in the MLF, whereas others such as projections from the anterior semicircular canal ascend through alternative pathways. [21] Lesions of INC produce poor vertical gaze-holding, torsional nystagmus, hypometric vertical saccades, and abnormal vertical vestibulo-ocular reflexes. [35]

Posterior commissure, in addition to conveying the crossing fibers from INC, also receives axons from the nucleus of the posterior commissure, which contributes to upgaze generation and coordination between lid and eye movements. [61] Lesions in it result in impaired upgaze and lid retraction or lid lag. [71]

Vergence

Motor commands for vergence are exerted by motoneurons of the medial rectus subnucleus of the oculomotor nuclear complex. There is some evidence that a certain group of the medial rectus motoneurons (i.e., dorsomedial, rostral subgroup C) that innervates the orbital layer of the medial rectus muscle selectively is involved in generating slow vergence responses. [12]

Premotor commands for vergence come from the rostral midbrain, or the so-called “midbrain near-response neurons” in the supraoculomotor area. Two different populations of premotor vergence cells have been identified in this region: (1) tonic, near response cells adjacent to the oculomotor nucleus that project to the medial rectus motoneurons to provide the vergence signal and (2) vergence burst cells that project to the pontine vergence integrator and to tonic near response cells. [51] There is a group of vergence burst neurons that discharges more for vergence associated with saccades than for a pure vergence, which may represent a substrate for saccade-vergence interaction during natural gaze shifts.

For tonically sustaining a particular vergence angle (vergence integration), NRTP is important. [32] Two types of cells were found in NRTP: cells that increase activity with near response and cells that increase activity with far response. Stimulation in the area causes changes in vergence angle and accommodation.

Disorders of Supranuclear Ocular Motor control

When confronting a patient with a given problem, the patient's level of dysfunction is not known in advance. Therefore, the disorders are listed according to a descriptive (rather than an orderly anatomic) approach that may be useful in bedside diagnosis.

Disorders of Horizontal Gaze

Unilateral representation of horizontal gaze control and the push-pull relationship between the corresponding areas of the two sides make minor dysfunction immediately detectable. The spectrum of the responsible pathology already starts on the nuclear level, as the abducens nucleus—in contrast to other cranial nerves nuclei—is in itself involved in supranuclear coordination of horizontal gaze.

Gaze Palsy

Damage to the abducens nucleus results in a rare but characteristic pattern of a “nuclear VI,” or inability to activate the ipsilateral lateral rectus and contralateral medial rectus for all types of conjugate eye movements, including vestibulo-ocular reflexes (“doll's eyes” maneuvers). [9] Vergence movements, however, may be spared. Nuclear VI usually is accompanied by ipsilateral peripheral facial weakness (because of the adjacent genu of the seventh nerve) and by esotropia (because of the possible concurrent involvement of the sixth nerve fascicle on the side of the lesion).

As opposed to loss of all conjugate eye movements seen with the nuclear VI palsy, selective impairment of ipsilateral horizontal saccades lesions of the PPRF. [36] [37] Bilateral selective defect of horizontal saccades occurs in degenerative conditions such as various types of spinocerebellar degenerations or Gaucher's disease. Isolated deficit of ipsilateral smooth pursuit occurs when pontine lesions affect the dorsolateral pontine nuclei, whereas cerebellar lesions can impair contralateral pursuit. [40] [82]

Internuclear Ophthalmoplegia

Lesions of the MLF result in impaired adduction during conjugate contralesional gaze and abducting nystagmus. The MLF lesion is on the side of poor adduction (Fig. 5).

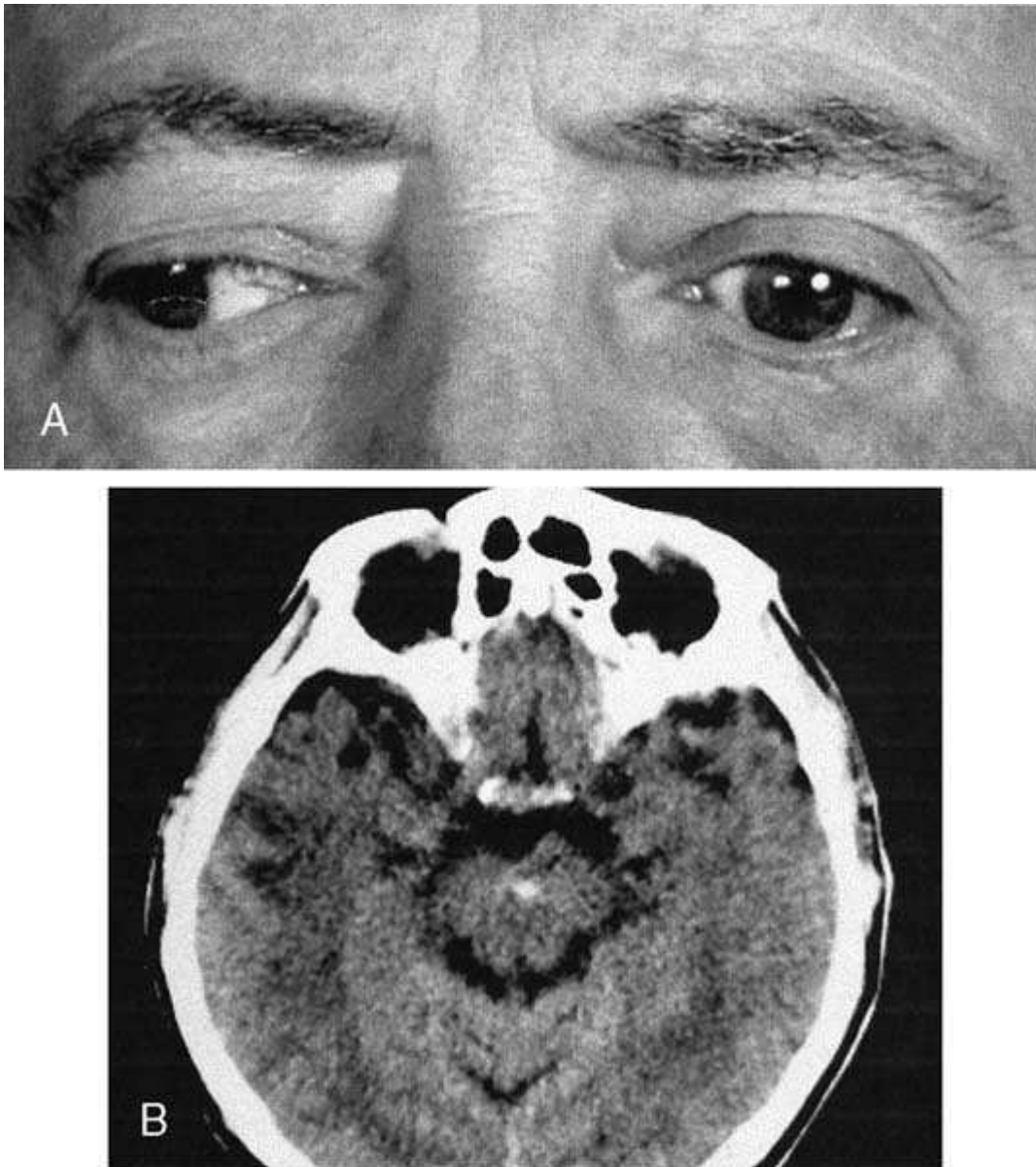

Fig. 5. Internuclear ophthalmoplegia in a 67-year-old man with recent onset of unsteadiness of gait. *A*, On right gaze, adduction of the left eye was limited. *B*, Brain CT scan demonstrated a small paramedian hemorrhage in the lower midbrain, involving the left medial longitudinal fasciculus.

The dissociate nystagmus of the abducting eye (contralateral to the lesion) reflects central adaptation in response to the adduction weakness.^[85] Similar dissociated nystagmus may be observed in a healthy agonist muscle with extraocular muscle weakness of any origin. Extensive damage to the MLF may be accompanied by skew deviation and dissociate vertical nystagmus (discussed later in this article). Subtle internuclear ophthalmoplegia (INO) may manifest as a slowing (without range limitation) of adduction as compared with abducting saccades. This discrepancy of the velocities can be demonstrated using an optokinetic tape.

Although medial rectus on the affected side seems weak, it often can be activated during convergence effort, as premotor vergence command reaches motoneurons of the medial rectus subnucleus from the rostral midbrain and not through the MLF. In some patients with INO, however, convergence is not preserved (Cogan's anterior INO). This classification of INO into anterior and posterior types according to preservation

of convergence does not help localize the responsible lesion to either pons or midbrain. Patients with unilateral INO do not complain of diplopia when looking straight ahead because they are orthotropic (or exophoric) unless accompanied by skew deviation. In contrast, patients with bilateral INO have exotropia—a syndrome termed *wall-eyed bilateral INO* (WEBINO). The most frequent cause of bilateral INO, especially in young adults, is multiple sclerosis (MS). Other causes include brainstem strokes, neoplastic processes, and trauma.

One-and-a-Half Syndrome

Lesions involving the MLF and the abducens nucleus on the same side cause palsy of all conjugate horizontal movements except for abduction in the contralateral eye. [63] In its partial form restricted for saccadic impairment, the one-and-a-half syndrome can arise from combined damage to the ipsilateral PPRF and MLF. Acutely, the patient may be exotropic (paralytic pontine exotropia). [74] This syndrome has been described with various processes affecting pons, such as stroke, MS, and tumors.

Impaired Eccentric Gaze-Holding

Lesions affecting the MVN and adjacent NPH invalidate the gaze-holding mechanism (neural integrator). [15] [80] As a result, during attempted horizontal gaze the eyes drift slowly toward the orbital midposition. Consequent corrective quick phases (saccades) produce the appearance of gaze-evoked nystagmus. The NPH and MVN are susceptible to toxic effects of numerous substances, including antiepileptic medications and lithium. They also suffer early in the course of thiamine deficiency. Gaze-evoked nystagmus may be a sensitive sign of Wernicke's encephalopathy or drug intoxication.

Saccadic Lateropulsion

In lateral medullary infarction (Wallenberg's syndrome), there is a characteristic change in saccades: ipsilateral horizontal saccades become hypermetric and deviate toward the side of the lesion (ipsipulsion). [27] Similar phenomenon affects vertical saccades with unwanted horizontal, ipsilesional curving of the trajectories. An explanation for lateropulsion lies in impaired cerebellar modulation of saccadic metrics secondary to dysfunction of the dorsal vermis and the fastigial nucleus. An infarcted inferior cerebellar peduncle in Wallenberg's syndrome results in inhibition of the ipsilateral fastigial nucleus, producing ipsipulsion of saccades. In the same vein, lesions affecting crossed outputs of the fastigial nucleus by way of the superior cerebellar peduncle result in contrapulsion that also is seen in midbrain disease.

Horizontal Gaze Deviations

Gaze deviations can be produced at several levels of the central nervous system, including the medulla, pons, thalamus, basal ganglia, and cerebral cortex. As a rule, eyes are deviated toward the side of the lesion with supratentorial lesions, whereas the deviation is contralesional with brainstem (pontine) lesions. There are several exceptions to this rule. With thalamic hemorrhages, the eyes deviate away from the lesion (wrong-way deviation). On the other hand, lower brainstem lesions resulting in Wallenberg's syndrome can cause the gaze to deviate ipsilesionally. Epileptic gaze deviation is always in the direction opposite to what would be expected from a destructive lesion in the same area.

The majority of gaze deviations are associated with large hemispheric lesions usually in the distribution of the middle cerebral artery and involving the parietal cortex. [24] Acutely, the eyes are shifted conjugately toward the side of the lesion (Fig. 6).

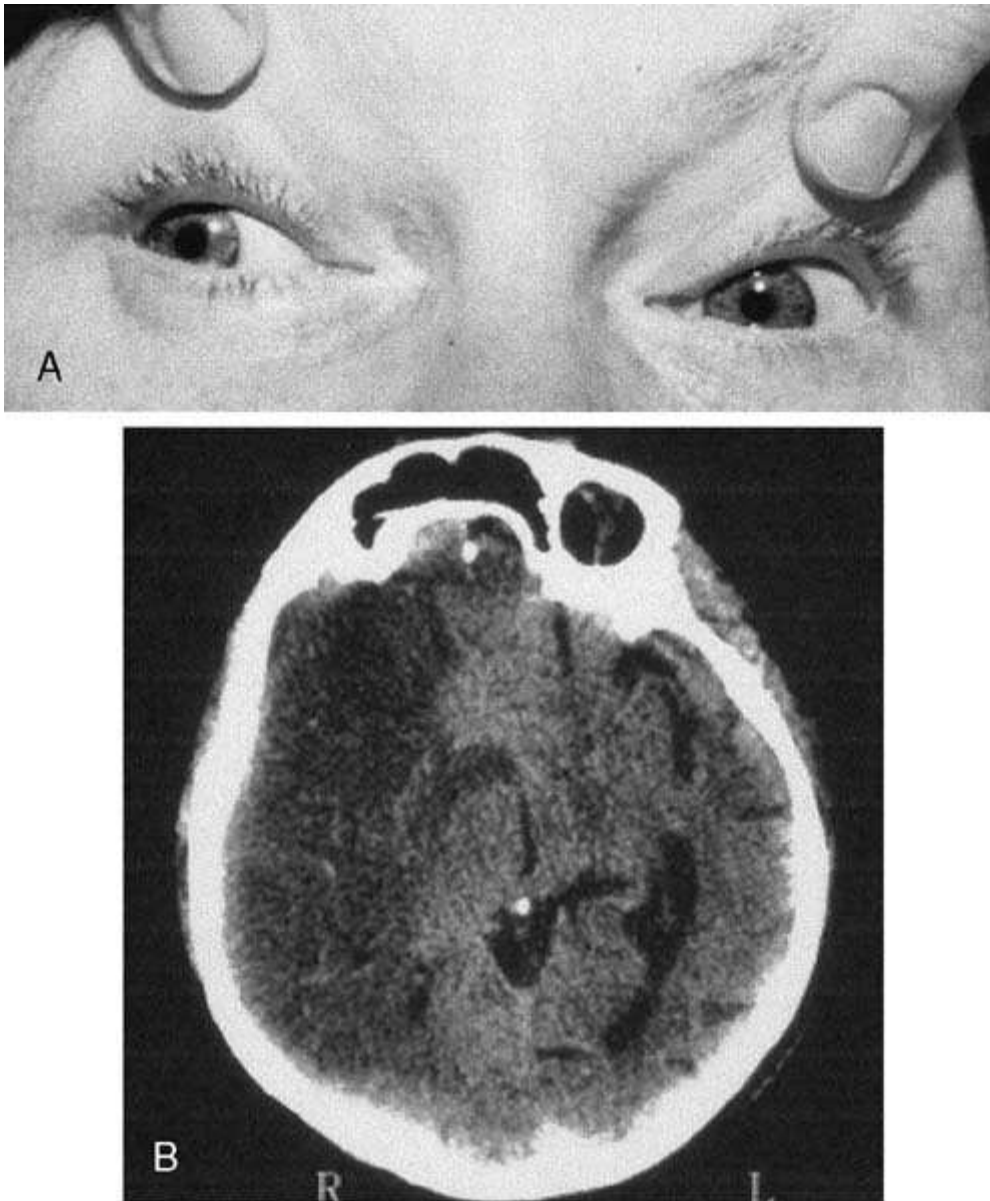


Fig. 6. Ipsilesional gaze deviation in a 63-year-old woman with acute onset of left hemiplegia. *A*, On opening her eyes, gaze was deviated to the right. *B*, Brain CT scan demonstrated massive infarction in the territory of right middle cerebral artery.

Vestibular manipulation (e.g., with caloric stimulation or oculo-cephalic maneuvers) usually elicits a full range of horizontal movement. This difference may help distinguish between hemispheric and pontine gaze deviations; in the latter, eyes cannot be driven into the paretic field by vestibulo-ocular reflexes. It should be noted that all gaze deviations are transient and disappear a few days after their onset. Eye deviation may be prolonged, however, if there has been previous damage to the other side of the brain. [76]

Disorders of Vertical Gaze

Because generation of pure vertical gaze shifts requires bilateral activation of the corresponding cortical and brainstem areas, unilateral lesions along the pathway are expected to result in relatively mild changes in vertical eye movements. To produce noticeable deficits of vertical gaze, damage has to be bilateral or midline and affect the crossing fibers from both right and left counterparts.

Unilateral lesions of the riMLF cause only a slowing of downward saccades, and upward saccades remain unchanged (perhaps reflecting the bilateral projections of riMLF to elevator muscles and ipsilateral projections to depressor muscles). Ipsitorisional saccades become markedly impaired (e.g., damage to the right riMLF causes inability to produce quick extorsion of the right eye and intorsion of the left eye), with tonic

contralesional torsional deviation. [37]

Bilateral experimental lesions of the riMLF in monkeys essentially abolish vertical saccades, whereas the rest of the eye movements are spared, including vertical gaze-holding, vestibular eye movements, pursuit, and horizontal saccades. [81] Similarly, patients with discrete, bilateral lesions (e.g., infarctions in the territory of the posterior thalamo-subthalamic artery) of the riMLF have markedly abnormal vertical saccades in the upward and downward direction. [10] Certain degenerative, metabolic, or infectious disorders selectively affect riMLF bilaterally, producing slow or absent vertical saccades (e.g., progressive supranuclear palsy, Niemann-Pick type C, Whipple's disease).

Eccentric vertical gaze-holding can be impaired by unilateral experimental lesions of the INC. These lesions are associated with skew deviation (discussed later), impaired vertical vestibulo-ocular reflex, and hypometric vertical saccades. The deficits are more pronounced with bilateral INC lesions. [35] In patient and animal studies, lesions of riMLF and INC are accompanied by torsional nystagmus. The direction of the nystagmus can help localize the lesion. With riMLF lesions the nystagmus is contralesional, whereas with INC lesions it is ipsilesional (in both cases, tonic torsional deviation is contralesional). [34]

Lesions of the posterior commissure produce loss of upward gaze. [62] Although all types of eye movements can become impaired, the vertical gaze-holding deficit (integrator failure) is the most profound. [61] Damage to the posterior commissure, with subsequent dysfunction of the crossing fibers from the INC, is the core of the so-called "dorsal midbrain syndrome" (Parinaud's syndrome). Several features characterize dorsal midbrain syndrome. Its most prominent feature is limitation of upward eye movements with downward bias of the resting eye position, also called the setting-sun sign (Fig. 7).

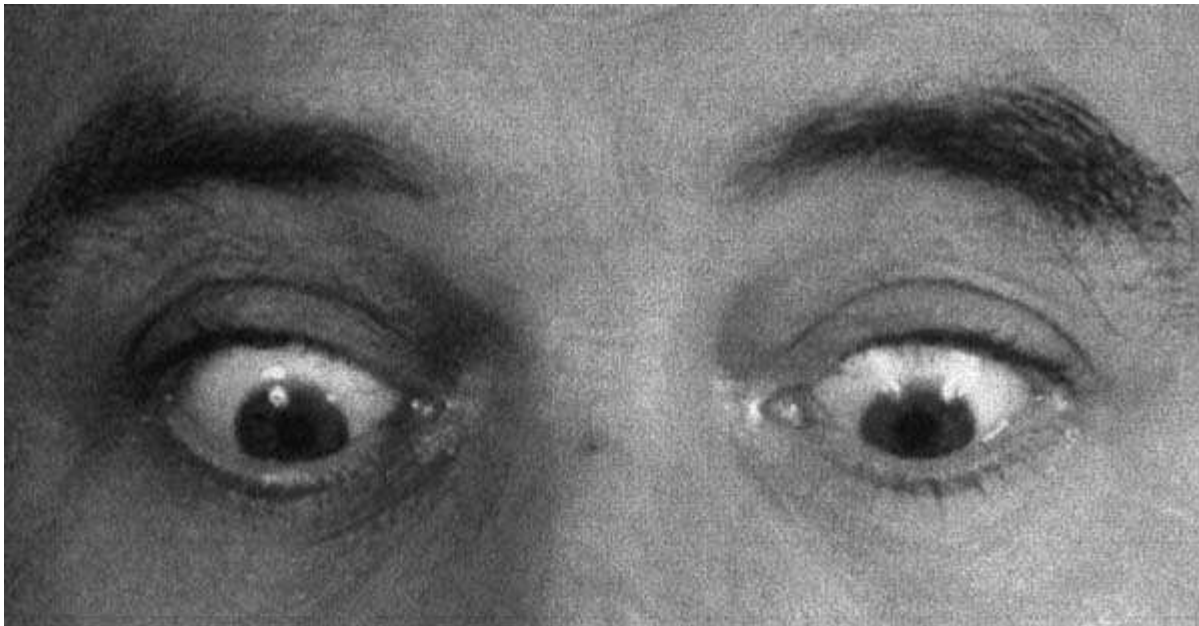

Fig. 7. Dorsal midbrain syndrome in a 45-year-old man with Chiari malformation and hydrocephalus caused by malfunction of a ventriculo-peritoneal shunt. Note downward bias of the eyes during attempted straight-ahead gaze and prominent eyelid retraction (Collier's sign).

There may be lid retraction when looking straight ahead (Collier's sign), convergence-retraction nystagmus at attempted upward gaze, pseudoabducens palsy, and mid-dilated pupils showing light-near dissociation. Convergence-retraction nystagmus can be provoked by making the patient watch a down-moving optokinetic tape. Refixation effort stimulates a series of repetitive upward saccades that each are substituted by a convergence movement. Cocontraction of the medial and lateral rectus produces globe retraction that is best evident by observing the patient's eye in profile. Increased vergence tone underlies bilateral limitation of abduction (pseudoabducens palsy). The most common causes of dorsal midbrain syndrome are pineal area tumors, midbrain infarction, and hydrocephalus (especially in children). [11] [47]

Skew deviation is a vertical ocular misalignment of supranuclear origin. Although classically comitant, the

hypertropia may vary or alternate with gaze position. Noncomitant skew can be distinguished from fourth nerve palsy by negative head tilt and the direction of cyclorotation. With skew deviation the hypertropic eye is incyclotorted, whereas with trochlear palsy it is excyclotorted (Fig. 8).

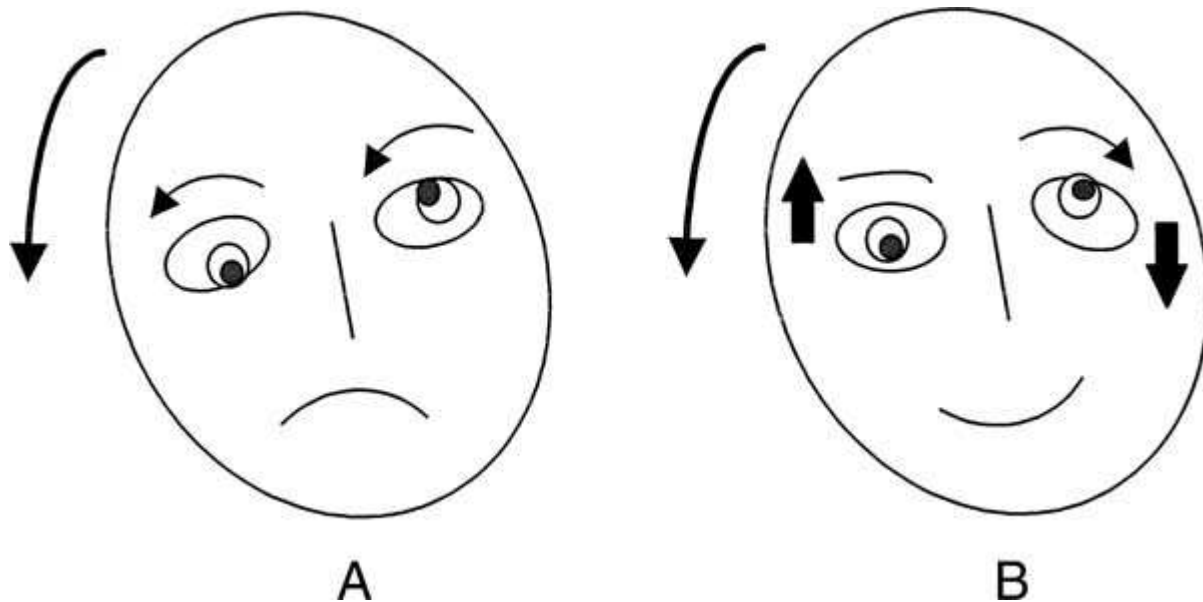


Fig. 8. Skew deviation versus IV nerve palsy. *A*, Right ocular tilt reaction (OTR) (*A*) and *B*, Left trochlear palsy (*B*). In both cases, there is left hypertropia that may be noncomitant, but torsional deviation of the hypertropic eye helps to distinguish between the two conditions. With IV nerve palsy, the hypertropic eye is excyclotorted, and the hypotropic eye has no cyclotropia. With OTR, the hypertropic eye is incyclotorted, and the hypotropic eye is excyclotorted (*curved arrows*). In OTR, spontaneous head tilt in the direction of torsional deviation does not eliminate vertical diplopia because it is not compensatory to ocular misalignment. In contrast, in IV nerve palsy, contralateral head tilt results in depression of the hypertropic eye and elevation of the hypotropic eye (*straight arrows*), thus alleviating diplopia.

Skew deviation is part of a more general ocular tilt reaction (OTR) that consists of head tilt, ocular torsion, and vertical skew (all in the same direction), in which torsional deviation is the most sensitive and consistent sign (see Fig. 8).^[8] Patients with OTR have deviation of the subjective visual vertical. OTR reflects imbalance of otolithic inputs. It can occur with lesions anywhere along this pathway, from the otolithic organs in the inner ear to the ipsilateral vestibular nuclei and up to the contralateral INC. Because central otolithic projections cross at the lower pontine level and run in the MLF to reach the contralateral INC,^[13] peripheral and lower brainstem lesions cause ipsilateral OTR, whereas high pontine and midbrain lesions produce contralateral OTR.^[7] Thus, lesions affecting the vestibular nerve result in the ipsilesional head tilt, hypotropia and excyclotorsion, and lesions involving the MLF and INC cause contralateral head tilt, hypertropia, and excyclotorsion (Fig. 9).

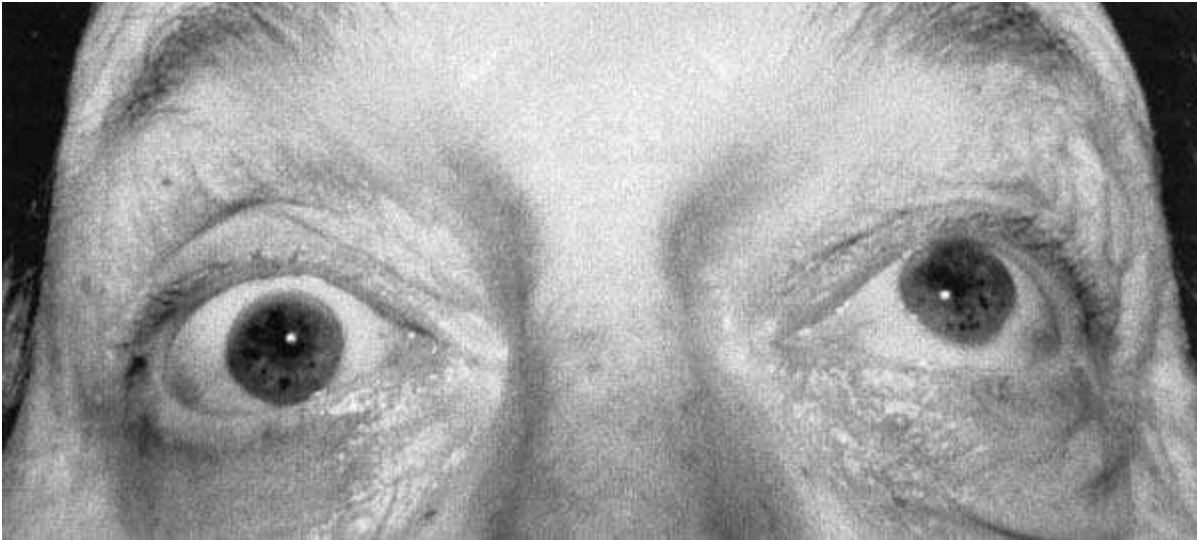


Fig. 9. Skew deviation (left hypertropia) in a 73-year-old patient with carcinoma of prostate and a metastatic lesion in the left midbrain involving left interstitial nucleus of Cajal and contralateral ocular tilt reaction.

In some patients with midbrain lesions, skew deviation may slowly alternate or change in magnitude over the course of minutes.^[19] Skew deviation has been described in a variety of disorders of the brainstem and cerebellum and as a transient phenomenon with phenytoin toxicity and increased intracranial pressure.^[29]

Combined Disorders of Horizontal and Vertical Gaze

Concurrent impairment of horizontal and vertical eye movements generally implies bilateral dysfunction on either the brainstem or hemispheric level. Whereas unilateral PPRF lesions affect only ipsilateral horizontal saccades, bilateral damage to PPRF results in slow vertical saccades and an inability to produce horizontal saccades in both directions. Similarly, whereas unilateral frontoparietal lesions cause abnormal contralesional horizontal saccades, bilateral lesions impair all voluntary eye movements, producing a so-called “acquired ocular motor apraxia.”^[47] ^[64] Reflex eye movements, including the vestibulo-ocular reflex and quick-phases of nystagmus, are preserved. Balint's syndrome refers to a triad of acquired ocular motor apraxia, optic ataxia (eye-hand incoordination with impaired reaching), and simultanagnosia (disturbance of visual attention outside the central visual field).^[38] This syndrome usually is observed with bilateral lesions of dorsolateral posterior cortex of whatever origin (i.e., structural or degenerative, such as Alzheimer's disease). The same clinical picture can be produced also by extensive bifrontal lesions.^[64]

Disorders of Vergence

Vergence abnormalities often do not carry grave diagnostic implications and are commonly associated with poor effort, functional disorders, or age-related phenomena. Occasionally, abnormal convergence may be the only sign of midbrain disease.

Convergence insufficiency is one of the most frequently missed causes of diplopia. Patients (mostly young adults) complain of eye strain and diplopia at near. Examination shows full range of movements but poor convergence amplitudes (measured with base-out prisms) and exotropia at near. The other two components of the near triad—accommodation and pupillary constriction—usually are preserved and attest to patient effort during near viewing. Using a precise eye movement recording technique, it has been confirmed that these patients benefit from orthoptic vergence exercises.^[83] Only a minority of patients has to resort to base-in prisms.

Spasm of the near reflex (convergence spasm) usually is psychogenic. Afflicted patients demonstrate unilateral or bilateral limitation of abduction; however, miosis on attempted lateral gaze gives the diagnosis away, indicating that instead of version, the patient employs a vergence movement, and the pupil constricts as a part of the near triad. Rarely, a tonic spasm of the near reflex may occur with organic midbrain disease.

^[67]

Divergence insufficiency is a rare and dubious clinical entity. It is characterized by orthophoria at near and comitant esotropia at far. The patients complain of diplopia while viewing distant objects. To make the diagnosis, abnormal abduction has to be ruled out, which means normal velocities of abducting saccades should be demonstrated. Divergence insufficiency has been reported in seizure disorders, progressive supranuclear palsy, and following viral infections, but in most instances saccadic velocities were not measured. Stern and Tomsak [77] described a patient who developed divergence insufficiency in the course of a recovery from sixth nerve palsy. The presence of an MR imaging lesion adjacent to the abducens nucleus raises the possibility of subtle sixth nerve dysfunction manifesting as divergence paralysis. One might speculate that lesions encroaching on an outer cap of the abducens nucleus affect fibers that are selectively responsible for tonic eye position and thus result in pure static ocular misalignment without slowing abducting saccades. Irrespective of the underlying pathophysiology, most patients benefit from base-out prisms incorporated in distant spectacle correction.

Disorders of Fixation

Steady fixation can be disrupted by two types of involuntary, abnormal eye movements: nystagmus and saccadic intrusions. The principal distinction between the two is the difference in initial pathologic eye movement, which is slow with nystagmus and quick with saccadic intrusions.

Acquired Nystagmus

Nystagmus is characterized by repetitive, to-and-fro involuntary eye movements that are initiated by a slow drift of the eye away from the object of interest, producing blurred vision and oscillopsia. The slow phase of nystagmus may be sinusoidal (pendular nystagmus) or unidirectional followed by corrective quick phases (jerk nystagmus). Conventionally, nystagmus is defined by the direction of its quick phases. Different pathophysiologic mechanisms underlie various forms of nystagmus. Here, however, it is preferred to approach nystagmus phenomenologically and describe it according to its waveforms (jerk versus pendular), the direction of the slow phase, and the dependency on the orbital position.

The two types of nystagmus that may not be evident when looking straight ahead are gaze-evoked and peripheral vestibular nystagmus. Gaze-evoked nystagmus is observed when the eyes are moved to extreme orbital positions. On attempted eccentric gaze, the eyes cannot be kept steady, and they drift toward the midposition. Corrective quick phases move the eyes back to the desired location. This type of nystagmus is caused by dysfunction of the neural integrator for horizontal eye movements, NPH and MVN, that may be secondary to structural lesions, or toxic-metabolic insult. Common causes include anticonvulsant medications, lithium, sedatives, alcohol, and Wernicke's encephalopathy. [47] [20] In the vertical plane, similar gaze-evoked nystagmus (upbeating on upgaze, downbeating on downgaze) occurs with midbrain lesions involving the INC. [35]

Peripheral vestibular nystagmus of a unilateral vestibular end-organ disease is mixed in direction. It is horizontal-torsional when the whole labyrinth is involved and vertical-torsional with individual vertical canals dysfunction (thus, in benign paroxysmal positional vertigo nystagmus usually is mixed upbeat-torsional). Slow phases are directed toward the diseased ear, and quick phases are directed away from the side of the lesion. Nystagmus intensity increases as the eyes are turned in the direction of the quick phase (Alexander's law), which is characteristic but not specific for peripheral vestibular nystagmus. Other features include fatigability and attenuation by fixation. At times, only preventing fixation (by Frenzel goggles or during ophthalmoscopy) can make nystagmus apparent.

Nystagmus that is present with eyes close to midposition includes forms of central vestibular nystagmus, acquired pendular nystagmus, and seesaw nystagmus. Central vestibular nystagmus is comprised of upbeat, downbeat, and torsional nystagmus and PAN. The conditions are characterized by a single plane of oscillation (e.g., pure vertical or pure torsional) and a lack of suppression by fixation. Central vestibular nystagmus usually obeys Alexander's law (i.e., it becomes more prominent while looking in the direction of quick phases). An efficient way to provoke downbeat nystagmus is to make patients look down and laterally. Upbeat nystagmus most commonly is reported with medullary lesions, which includes lesions in the perihypoglossal nuclei and adjacent vestibular nuclei. Downbeat nystagmus usually occurs with lesions of the vestibulocerebellum and underlying medulla, especially at the craniovertebral junction. One explanation for

these clinical associations is differential anatomy and pharmacology of central projections subserving anterior and posterior semicircular canals. These properties dictate an inherent physiologic upward bias that normally is counteracted by cerebellar flocculus. With floccular dysfunction, however, the imbalance becomes overt, resulting in an upward drift of the eyes with corrective downward saccades (i.e., downbeat nystagmus). Upbeat and downbeat nystagmus occasionally respond to clonazepam (gamma-aminobutyric acid [GABA]-A agonist) and baclofen (GABA-B agonist). Pure torsional nystagmus is uncommon. It has been reported with MS, infarction (including Wallenberg's syndrome), arteriovenous malformation, tumors, and syringobulbia involving the vestibular nuclei. [49] PAN is a rare form of central vestibular nystagmus in which horizontal jerk nystagmus, present when looking straight ahead, reverses its direction about every two minutes. Acquired PAN occurs most commonly with disease involving the midline cerebellum. The underlying pathophysiology involves abnormal prolongation of the velocity-storage mechanism [8] that induces compensatory reversal of nystagmus direction, thus creating PAN. Experimental ablation of the cerebellar nodulus and uvula in monkeys serves as a model for PAN. [45] Acquired PAN responds to treatment with GABA-B agonist baclofen. [33]

Acquired pendular nystagmus (APN) is one of the more common types of nystagmus. It produces severe oscillopsia and visual deterioration and often has horizontal, vertical, and torsional components. Depending on synchronization between the different components, the trajectory can be oblique, elliptical, or circular. The oscillation may be disconjugate or even monocular, and at times the phase shift between the eyes reaches 180°, so that nystagmus becomes convergent–divergent. [1] Its pathogenesis remains unclear. It has been suggested that APN may be caused by instability (excessive activity) in the network of the neural integrator. [23] APN is encountered in a variety of conditions affecting the brainstem and cerebellum, including MS, acute brainstem stroke, oculopalatal myoclonus, spinocerebellar degenerations, and Whipple's disease. [46] In a double-blind study of APN, gabapentin (a GABAergic antiepileptic medication) was found to be effective in suppressing nystagmus and alleviating oscillopsia. [4]

Seesaw nystagmus is a pendular oscillation in which one half cycle consists of elevation and intorsion of one eye and synchronous depression and extorsion of the other eye with the vertical and torsional movements reversing during the next half cycle. Seesaw nystagmus has been associated with parasellar tumors, suggesting a role of crossing fibers of the optic nerves in its pathogenesis. The importance of primary visual impairment in producing seesaw nystagmus is strengthened by its development in patients with progressive visual loss (e.g. caused by retinitis pigmentosa). [50] Seesaw nystagmus also has been described in patients with discrete lesions involving the INC, implying a central disturbance of otolithic inputs in the pathogenesis; however, a recent study of INC inactivation failed to produce seesaw nystagmus. [69]

Saccadic intrusions are abnormal quick eye movements that intrude on steady fixation. They range from a single saccade to sustained oscillations. Oscillopsia is not a characteristic feature of individual saccadic intrusions, owing to visual suppression that occurs normally during a saccade. Oscillopsia may occur with a continuous saccadic oscillation in which eyes are repeatedly taken across the fixation target. Saccadic intrusions are divided into two categories: intrusions with and without normal individuals. Multiple square wave jerks, at times to the extent of a continuous square wave oscillation, are found in a variety of neurologic disorders, including cerebellar degenerations and progressive supranuclear palsy, and following pallidotomy. [6] Square wave pulses are large saccades that take the eyes off fixation, separated by intersaccadic intervals of about 100 ms. They occur in MS (macrosquare wave jerks). Macrosaccadic oscillations consist of spindle-shaped bursts of mainly horizontal saccades that crescendo–decrescendo in amplitude and have intersaccadic intervals of about 200 ms. Reported mostly in cerebellar patients, macrosaccadic oscillations probably reflect saccadic dysmetria with continuous overshoot of the target. [2] [73]

Saccadic intrusions without intersaccadic intervals include ocular flutter and opsoclonus. Ocular flutter is a burst of back-to-back saccades in which the oscillation is confined to one direction (usually horizontal, but they also may be diagonal). Multivectorial (i.e., continuously changing the plane of oscillation) back-to-back saccades are termed opsoclonus. Flutter and opsoclonus seem to represent a clinical spectrum. They are encountered in patients with brainstem or cerebellar disease (e.g., brainstem encephalitis or paraneoplastic syndromes). [3] One speculative explanation for opsoclonus is dysfunction of the brainstem omnipause neurons, which are responsible for regulation of saccadic burst neurons. [70]

References

1. Averbuch-Heller L, Zivotofsky AZ, Remler BF, et al: Convergent–divergent pendular nystagmus: Possible role of the vergence system. *Neurology* 45:509, 1995 **Abstract**
2. Averbuch-Heller L, Kori AA, Rottach KG, et al: Dysfunction of pontine omnipause neurons causes impaired fixation: Macrosaccadic oscillation with a unilateral pontine lesion. *Neuroophthalmology* 16:99, 1996
3. Averbuch-Heller L, Remler B: Opsoclonus. *Semin Neurol* 16:21, 1996 **Abstract**
4. Averbuch-Heller L, Tusa RJ, Fuhry L, et al: A double-blind controlled study of gabapentin and baclofen as treatment for acquired nystagmus. *Ann Neurol* 41:818, 1997 **Abstract**
5. Averbuch-Heller L, Lewis RF, Zee DS: Disconjugate adaptation of saccades: Contribution of binocular and monocular mechanisms. *Vision Res* 39:341, 1999 **Abstract**
6. Averbuch-Heller L, Stahl JS, Hlavín ML, Leigh RJ: Square-wave jerks induced by pallidotomy in parkinsonian patients. *Neurology* 52:185, 1999 **Full Text**
7. Brandt T, Dieterich M: Pathological eye–head coordination in roll: Tonic ocular tilt reaction in mesencephalic and medullary lesions. *Brain* 110:649, 1987 **Abstract**
8. Brandt T, Dieterich M: Vestibular syndromes in the roll plane: Topographic diagnosis from brainstem to cortex. *Ann Neurol* 36:337, 1994 **Abstract**
9. Bronstein AM, Morris J, Du Boulay G, et al: Abnormalities of horizontal gaze: Clinical, oculographic and magnetic resonance imaging findings: I. Abducens palsy. *J Neurol Neurosurg Psychiatry* 53:194, 1990 **Abstract**
10. Büttner-Ennever JA, Büttner U, Cohen B, et al: Vertical gaze paralysis and the rostral interstitial nucleus of the medial longitudinal fasciculus. *Brain* 105:125, 1982 **Abstract**
11. Büttner-Ennever JA, Acheson JF, Büttner U, et al: Ptosis and supranuclear downgaze paralysis. *Neurology* 39:385, 1989 **Abstract**
12. Büttner-Ennever JA, Cohen B, Horn AK, et al: Pretectal projections to the oculomotor complex of the monkey and their role in eye movements. *J Comp Neurol* 366:348,1996 **Abstract**
13. Büttner-Ennever JA: A review of otolith pathways to brainstem and cerebellum. *Ann N Y Acad Sci* 871:51,1999 **Abstract**
14. Büttner-Ennever JA, Horn AK, Henn V, et al: Projections from the superior colliculus motor map to omnipause neurons in monkey. *J Comp Neurol* 413:55, 1999 **Abstract**
15. Cannon SC, Robinson DA: Loss of the neural integrator of the oculomotor system from brain stem lesions in monkey. *J Neurophysiol* 57:1383, 1987 **Abstract**
16. Chimoto S, Iwamoto Y, Yoshida K: Projections and firing properties of down eye-movement neurons in the interstitial nucleus of Cajal in the cat. *J Neurophysiol* 81:1199, 1999 **Abstract**
17. Clendaniel RA, Mays LE: Characteristics of antidromically identified oculomotor internuclear neurons during vergence and versional eye movements. *J Neurophysiol* 71:1111, 1994 **Abstract**
18. Cohen B, Henn V, Raphan T, et al: Velocity storage, nystagmus, and visual-vestibular interactions in humans. *Ann N Y Acad Sci* 374:421, 1981 **Citation**
19. Corbett JJ, Schatz NJ, Shults WT, et al: Slowly alternating skew deviation: Description of a pretectal syndrome in three patients. *Ann Neurol* 10:540, 1981 **Abstract**
20. Corbett JJ, Jacobson DM, Thompson HS, et al: Downbeating nystagmus and other ocular motor defects caused by lithium toxicity. *Neurology*

39:481, 1989 [Abstract](#)

21. Cremer PD, Migliaccio AA, Halmagyi GM, et al: Vestibulo-ocular reflex pathways in internuclear ophthalmoplegia. *Ann Neurol* 45:529, 1999 [Abstract](#)

22. Dalezios Y, Scudder CA, Highstein SM, et al: Anatomy and physiology of the primate interstitial nucleus of Cajal: II. Discharge pattern of single efferent fibers. *J Neurophysiol* 80:3100, 1998 [Abstract](#)

23. Das VE, Oruganti P, Kramer PD, et al: Experimental tests of a neural-network model for ocular oscillations caused by disease of central myelin. *Exp Brain Res* 133:189, 2000 [Abstract](#)

24. De Renzi E, Colombo A, Faglioni P, et al: Conjugate gaze paresis in stroke patients with unilateral damage. *Arch Neurol* 39:482, 1982 [Abstract](#)

25. Dias E, Kiesau M, Segraves MA: Acute activation and inactivation of macaque frontal eye field with GABA-related drugs. *J Neurophysiol* 6:2744, 1995 [Abstract](#)

26. Dias EC, Segraves MA: Muscimol-induced inactivation of monkey frontal eye field: effects on visually and memory-guided saccades. *J Neurophysiol* 81:2191, 1999 [Abstract](#)

27. Dieterich M, Brandt T: Wallenberg's syndrome: Lateropulsion, cyclorotation and subjective visual vertical in 36 patients. *Ann Neurol* 31:399, 1992 [Abstract](#)

28. Ferraina S, Pare M, Wurtz RH: Disparity sensitivity of frontal eye field neurons. *J Neurophysiol* 83:625, 2000 [Abstract](#)

29. Frohman LP, Kupersmith MJ: Reversible vertical ocular deviations associated with raised intracranial pressure. *J Clin Neuroophthalmol* 5:158, 1985 [Abstract](#)

30. Fuchs AF, Robinson FR, Straube A: Role of caudal fastigial nucleus in saccade generation: I. Neuronal discharge patterns. *J Neurophysiol* 70:1723, 1993 [Abstract](#)

31. Fuchs AF, Robinson FR, Straube A: Participation of the caudal fastigial nucleus in smooth-pursuit eye movements: I. Neuronal activity. *J Neurophysiol* 72:2714, 1994 [Abstract](#)

32. Gamlin PD, Clarke RJ: Single-unit activity in the primate nucleus reticularis tegmenti pontis related to vergence and ocular accommodation. *J Neurophysiol* 73:2115, 1995 [Abstract](#)

33. Halmagyi GM, Rudge P, Gresty MA, et al: Treatment of periodic alternating nystagmus. *Ann Neurol* 8:609, 1980 [Abstract](#)

34. Helmchen CC, Glasauer S, Bartl K, et al: Contralesionally beating torsional nystagmus in a unilateral rostral midbrain lesion. *Neurology* 47:482, 1996 [Full Text](#)

35. Helmchen C, Rambold H, Fuhry L, et al: Deficits in vertical and torsional eye movements after uni- and bilateral muscimol inactivation of the interstitial nucleus of Cajal of the alert monkey. *Exp Brain Res* 119:436, 1998 [Abstract](#)

36. Henn V, Lang W, Hepp K, et al: Experimental gaze palsies in monkeys and their relation to human pathology. *Brain* 107:619, 1984 [Abstract](#)

37. Henn V, Hepp K, Vilis T: Rapid eye movement generation in the primate: Physiology, pathophysiology, and clinical implications. *Rev Neurol (Paris)* 145:540, 1989 [Abstract](#)

38. Husain M, Stein J: Rezso Balint and his most celebrated case. *Arch Neurol* 45:89, 1988 [Abstract](#)

39. Izawa Y, Sugiuchi Y, Shinoda Y: Neural organization from the superior colliculus to motoneurons in the horizontal oculomotor system of the cat. *J Neurophysiol* 81:2597, 1999 [Abstract](#)

40. Johnston JL, Sharpe JA, Morrow MJ: Paresis of contralateral smooth pursuit and normal vestibular smooth eye movements after unilateral

brainstem lesions. *Ann Neurol* 31:495, 1992 **Abstract**

41. King WM, Lisberger SG, Fuchs AF: Responses of fibers in medial longitudinal fasciculus of alert monkeys during horizontal and vertical conjugate eye movements evoked by vestibular or visual stimuli. *J Neurophysiol* 39:1135, 1976 **Abstract**

42. Kokkoroyannis T, Scudder CA, Balaban CD, et al: Anatomy and physiology of the primate interstitial nucleus of Cajal I: Efferent projections. *J Neurophysiol* 75:725, 1996 **Abstract**

43. Krauzlis RJ, Basso MA, Wurtz R: Shared motor error for multiple eye movements. *Science* 276:1693–1695, 1997 **Abstract**

44. Langer T, Kaneko CRS, Scudder CA, et al: Afferents to the abducens nucleus in the monkey and cat. *J Comp Neurol* 245:379, 1986 **Abstract**

45. Leigh RJ, Robinson DA, Zee DS: A hypothetical explanation for periodic alternating nystagmus: Instability in the optokinetic-vestibular system. *Ann N Y Acad Sci* 374:619, 1981 **Citation**

46. Leigh RJ, Averbuch-Heller L: Nystagmus and related disorders. *In* Miller NR, Newman NJ (eds): *Walsh and Hoyt's Clinical Neuro-ophthalmology*, vol 1, ed 5. Baltimore, Williams and Wilkins, 1998, p 1461

47. Leigh RJ, Zee DS: *The Neurology of Eye Movements*, ed 3. New York, Oxford University Press, 1999

48. Lisberger SG, Miles FA, Zee DS: Signals used to compute errors in monkey vestibuloocular reflex: Possible role of flocculus. *J Neurophysiol* 52:1140, 1984 **Abstract**

49. Lopez L, Bronstein AM, Gresty MA, et al: Torsional nystagmus: A neuro-otological and MRI study of thirty-five cases. *Brain* 115:1107, 1992 **Abstract**

50. May EF, Truxal AR: Loss of vision alone may result in seesaw nystagmus. *J Neuroophthalmol* 17:84, 1997 **Abstract**

51. Mays LE, Gamlin PD: Neuronal circuitry controlling the near response. *Curr Opin Neurobiol* 5:763, 1995 **Abstract**

52. Miles FA: The neural processing of 3-D visual information: Evidence from eye movements. *Eur J Neurosci* 10:811, 1998 **Abstract**

53. Miller NR, Newman NJ: The ocular motor system. *In* Miller NR, Newman NJ (eds): *Walsh and Hoyt's Clinical Neuro-ophthalmology*, vol 1, ed 5. Baltimore, Williams & Wilkins, 1998, pp 1043–1505

54. Moschovakis AK, Scudder CA, Highstein SM: A structural basis for Hering's law: Projections to extraocular motoneurons. *Science* 248:1118, 1990 **Abstract**

55. Moschovakis AK, Scudder CA, Highstein SM: Structure of the primate oculomotor burst generator: I. Median-lead burst neurons with upward on-directions. *J Neurophysiol* 65:203, 1991 **Abstract**

56. Moschovakis AK, Scudder CA, Highstein SM: Structure of the primate oculomotor burst generator: II. Median-lead burst neurons with downward on-directions. *J Neurophysiol* 65:218, 1991 **Abstract**

57. Munoz DP, Wurtz RH: Saccade-related activity in monkey superior colliculus: I. Characteristics of burst and buildup cells. *J Neurophysiol* 73:2313, 1995 **Abstract**

58. Munoz DP, Wurtz RH: Saccade-related activity in monkey superior colliculus: II. Spread of activity during saccades. *J Neurophysiol* 73:2334, 1995 **Abstract**

59. Nguyen LT, Baker R, Spencer RF: Abducens internuclear and ascending tract of Deiters inputs to medial rectus motoneurons in the cat oculomotor nucleus: Synaptic organization. *J Comp Neurol* 405:141, 1999 **Abstract**

60. Noda H, Fujikado T: Topography of the oculomotor area of the cerebellar vermis in macaques as determined by microstimulation. *J Neurophysiol* 58:359, 1987 **Abstract**

61. Partsalis AM, Highstein SM, Moschovakis AK: Lesions of the posterior commissure disable the vertical neural integrator of the primate oculomotor system. *J Neurophysiol* 71:2582, 1994 **Abstract**
62. Pasik P, Pasik T, Bender MB: The pretectal syndrome in monkeys: I. Disturbances of gaze and body posture. *Brain* 92:521, 1969 **Citation**
63. Pierrot-Deseilligny C, Chain F, Serdaru M, et al: The "one-and-a-half" syndrome: Electro-oculographic analyses of five cases with deductions about the physiological mechanisms of lateral gaze. *Brain* 104:665, 1981 **Citation**
64. Pierrot-Deseilligny C, Gautier J-C, Loron P: Acquired ocular motor apraxia due to bilateral fronto-parietal infarcts. *Ann Neurol* 23:199, 1988 **Abstract**
65. Pierrot-Deseilligny C, Rosa A, Masmoudi K, et al: Saccade deficits after a unilateral lesion affecting the superior colliculus. *J Neurol Neurosurg Psychiatry* 54:1106, 1991 **Abstract**
66. Pierrot-Deseilligny C, Israël I, Berthoz A, et al: Role of the different frontal lobe areas in the control of the horizontal component of memory-guided saccades in man. *Exp Brain Res* 95:166, 1993 **Abstract**
67. Rabinowitz L, Chrousos GA, Cogan DG: Spasm of the near reflex associated with organic disease. *Am J Ophthalmol* 103:582, 1987 **Abstract**
68. Ramat S, Das VE, Somers JT, et al: Tests of two hypotheses to account for different-sized saccades during disjunctive gaze shifts. *Exp Brain Res* 129:500, 1999 **Abstract**
69. Rambold H, Helmchen C, Büttner U: Unilateral muscimol inactivations of the interstitial nucleus of Cajal in the alert rhesus monkey do not elicit seesaw nystagmus. *Neurosci Lett* 272:75, 1999 **Abstract**
70. Ridley A, Kennard C, Schlotz CL, et al: Omnipause neurons in two cases of opsoclonus associated with oat-cell carcinoma of the lung. *Brain* 110:1699, 1987 **Abstract**
71. Schmidtke K, Büttner-Ennever JA: Nervous control of eyelid function: A review of clinical, experimental and pathological data. *Brain* 115:227, 1992 **Abstract**
72. Segraves MA, Goldberg ME, Deng S-Y, et al: The role of striate cortex in the guidance of eye movements in the monkey. *J Neurosci* 7:3040, 1987 **Abstract**
73. Selhorst JB, Stark L, Ochs AL, et al: Disorders in cerebellar ocular motor control: II. Macrosaccadic oscillation: An oculographic, control system and clinico-anatomical analysis. *Brain* 99:509, 1976 **Abstract**
74. Sharpe JA, Rosenberg MA, Hoyt WF, et al: Paralytic pontine exotropia: A sign of acute unilateral pontine gaze palsy and internuclear ophthalmoplegia. *Neurology* 24:1076, 1974 **Citation**
75. Sommer MA, Wurtz RH: Frontal eye field neurons orthodromically activated from the superior colliculus. *J Neurophysiol* 80:3331, 1998 **Abstract**
76. Steiner I, Melamed E: Conjugate eye deviation after acute hemispheric stroke: Delayed recovery after previous contralateral frontal lobe damage. *Ann Neurol* 16:509, 1984 **Abstract**
77. Stern RM, Tomsak RL: Magnetic resonance images in a case of "divergence paralysis". *Surv Ophthalmol* 30:397, 1986 **Abstract**
78. Strassman A, Highstein SM, McCrea RA: Anatomy and physiology of saccadic burst neurons in the alert squirrel monkey: I. Excitatory burst neurons. *J Comp Neurol* 249:337, 1986 **Abstract**
79. Strassman A, Highstein SM, McCrea RA: Anatomy and physiology of saccadic burst neurons in the alert squirrel monkey: II. Inhibitory burst neurons. *J Comp Neurol* 249:358, 1986 **Abstract**
80. Straube A, Kurzan R, Büttner U: Differential effects of bicuculline and muscimol microinjections into the vestibular nuclei on simian eye movements. *Exp Brain Res* 86:347, 1991 **Abstract**

81. Suzuki Y, Büttner-Ennever J, Straumann D, et al: Deficits in torsional and vertical rapid eye movements and shift of the Listing's plane after uni- and bilateral lesions of the rostral interstitial nucleus of the medial longitudinal fasciculus. *Exp Brain Res* 106:215, 1995 **Abstract**
82. Thier P, Bachor A, Faiss J, et al: Selective impairment of smooth-pursuit eye movements due to an ischemic lesion of the basal pons. *Ann Neurol* 29:443, 1991 **Abstract**
83. Van Leeuwen AF, Westen MJ, van der Steen J, et al: Gaze-shift dynamics in subjects with and without symptoms of convergence insufficiency: Influence of monocular preference and the effect of training. *Vision Res* 39:3095, 1999 **Abstract**
84. Vilis T, Hepp K, Schwartz U, et al: On the generation of vertical and torsional rapid eye movements in the monkey. *Exp Brain Res* 77:1, 1989 **Abstract**
85. Zee DS, Hain TC, Carl JR: Abduction nystagmus in internuclear ophthalmoplegia. *Ann Neurol* 21:383, 1987 **Abstract**
86. Zee DS, FitzGibbon EJ, Optican LM: Saccade-vergence interactions in humans. *J Neurophysiol* 68:1624, 1992 **Abstract**
87. Zhang H, Gamlin PD: Neurons in the posterior interposed nucleus of the cerebellum related to vergence and accommodation: I. Steady-state characteristics. *J Neurophysiol* 79:1255, 1998 **Abstract**
88. Zhou W, King WM: Binocular eye movements not coordinated during REM sleep. *Exp Brain Res* 117:153, 1997 **Abstract**
89. Zhou W, King WM: Premotor commands encode monocular eye movements. *Nature* 393:692, 1998 **Abstract**

Copyright © 2009 Elsevier Inc. All rights reserved. - www.mdconsult.com

Bookmark URL: [/das/journal/view/0/N/11834610?ja=276464&PAGE=1.html&issn=0896-1549&source=](http://das/journal/view/0/N/11834610?ja=276464&PAGE=1.html&issn=0896-1549&source=)